On The Right Track, For Precise Results

Apollo DIAGNOSTICS®
Expertise. Empowering you.

AD Express

July 2023

Editorial board

From the Editors' Desk

Dear Reader,

The future portends well for laboratory medicine. The advent of evidence-based medicine, the ever-growing advances in laboratory medicine & the ongoing COVID pandemic, have crystallized the importance of the laboratory & the role of the IVD industry in healthcare. Apollo Diagnostics has tapped into the immense potential & opportunity that looms large in India, where a still significant number of laboratories belong to the unorganized fold.

In this seventh edition of the year, we share an interesting repertoire of topics. Our first case report is about an archaic foe, which continues to resurface time & again. Bone & soft tissue tumors can pose significant diagnostic challenge & we share first case of vulvalmyofibroblastoma reported in India.

Astute clinical judgment & knowledge of the physiological basis of poisoning is important in clinical practice. Organophosphorous poisoning continues to be an issue to contend with especially in rural India. Dr.Maruthi Prasad & Dr.Rajesh Battina detail the subtle nuances of how cholinesterase results are to be interpreted. Patient safety has never been so important & Apollo has always been a leader in the patient safety front. Our second article stresses &advocates the importance of patient safety in the Total testing process (TTP).

Weexpect our creative tendencies to gravitate towards biochemistry ballads, serology sonnets & musings from microbiology in the forthcoming issues. In a first attempt we share riddles& quiz on 'Epithelium.' We have introduced another dimension to our quizzes by introducing 'know your mould.' A strong background of morphology will augur good for any laboratory & a quiz on the above lines will help microscopists appreciate morphology better.

We thank the contributors for taking time to put pen to paper & covering a gamut of topics with aplomb. AD express has gained considerable impetus by the way of your contributions & we welcome more from you all.Also humbly request you to share your feedback on 'AD express'& we assure you that feedback from you will make each next issue ever more interesting!

Wishing you all a happy reading & a great year ahead!

Best regards,

Dr. Marquess Raj M.D. Dip. N.B (Path), MBA (HM)
ZTC – TN & Pondicherry
marquess.raj@apollodiagnostics.in

Dr. Shalini Singh M.D (Path), IFCAP, DMSC (Endocrine)
Lab Director, Global reference lab, Hyderabad
shalini.singh@apolloclinic.com

Contents

CASE REPORT

1. A case report of Filarial Epididymo-orchitis

Dr. Anumoy Mukherjee (Consultant Pathologist, Apollo Diagnostics, Regional reference laboratory, Kolkata)

Dr. Riju Bhattacharya (Consultant Pathologist, Apollo Diagnostics, Regional reference laboratory, Kolkata)

Dr. Abhik Banerjee (Zonal Technical Chief- East Zone, Apollo Diagnostics, Regional reference laboratory, Kolkata)

Introduction:

Filarial Epididymo-orchitis is basically an inflammation of epididymis and testis which occurs as sequelae in chronic Filariasis. Death of the filarial worms, which may be precipitated by secondary bacterial infection, is one of the common manifestations of Filariasis (1).

India contributes to 40% of the global burden of Filariasis, with an estimated 553.7 million people at risk for lymphatic Filariasis (2).

Case history:

A 37 years old young male visited surgery outpatient department of a private hospital in Purulia, West Bengal with complaints of redness, swollen, painless scrotum.

There was no history of trauma, fever, infertility, lymphadenitis, lymphangitis, or previous history of testicular tumor.

On physical examination:

- The right testis was found to be slightly enlarged, firm, and non-tender on palpation.
- Right sided spermatic cord was also red, engorged, swollen.
- Left sided testis as well as spermatic cord was unremarkable.
- There was no inguinal lymphadenopathy.

Complete blood count (CBC) was advised by physician but report was unavailable. Immediate hospitalization was advised and an emergency right sided orchiectomy was planned. Debridement of scrotal skin and right orchiectomy was done and specimen of right testis with necrotic skin was sent to Apollo Diagnostics, Regional reference laboratory, Kolkata for Histopathological examination.

Gross examination-

Showed a specimen of testis with spermatic cord.

- The testis measured 6*4.5*4 cm.
- Attached spermatic cord was 6 cm in length.
- The epididymis showed greyish, necrotic as well as indurated areas.
- A separate skin covered tissue with ulcerated areas measuring 7*6*2 cm was also received along with the specimen in the same container.
- Multiple sections were taken from spermatic cord, testis, testis with thickened tunica and skin covered ulcerated area and processed as per standard grossing guidelines.

Microscopic examination-

- Sections from spermatic cord show few degenerating filarial nematodes surrounded by dense, mixed, inflammatory infiltrate composed lymphoplasmacytic cells & abundant eosinophils.
- Sections from testis and epididymis show filarial bodies surrounded by necrosis, foreign body giant cells & dense mixed inflammatory infiltrate composed of neutrophils, eosinophils, plasma cells & lymphocytes. Normal appearing seminiferous tubules were present at places.
- Section from skin covered tissue showednecroinflammatory infiltrate. No evidence of malignancy was seen.

The case was reported as Filarial Epididymo-orchitis. An advice of clinico-pathological correlation was suggested along with necessary radiological (ultrasonography) and other blood-based investigations.

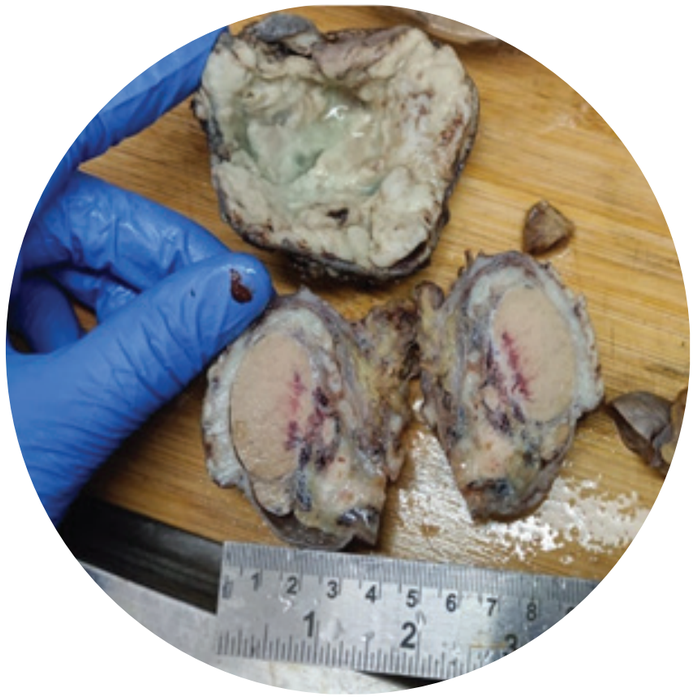

Fig 1. Cut open testis with Epididymis showing greyish, necrotic and indurated areas

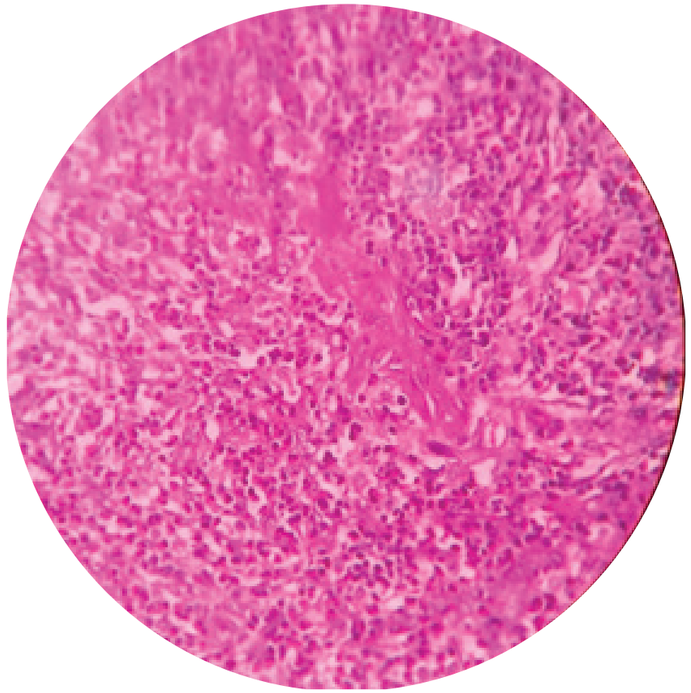

Fig 2. Testicular tissue showing dense inflammatory reaction composed of eosinophil's, neutrophils, lymphocytes and necrotic debris (H&E 50X)

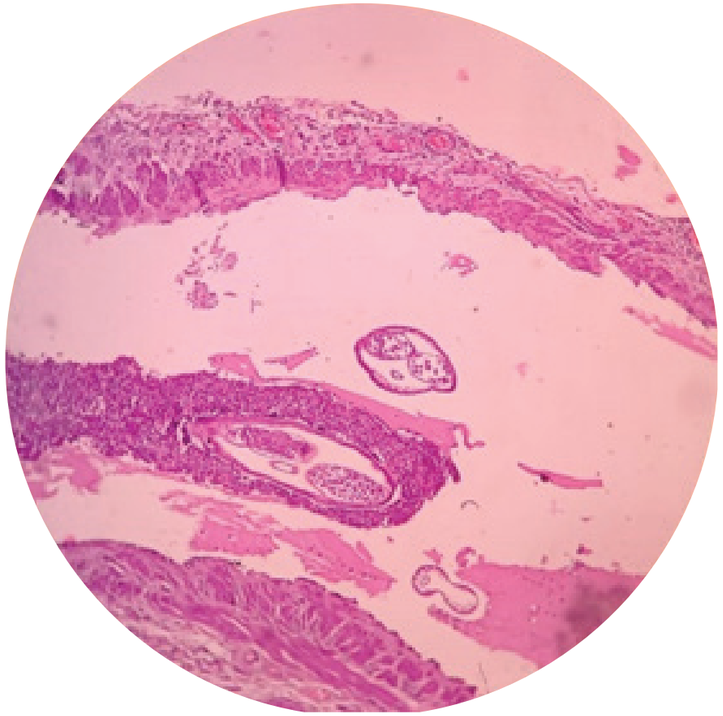

Fig 3. Spermatic cord showing degenerating filarial nematode surrounded by dense, mixed, inflammatory infiltrate (H & E 100X)

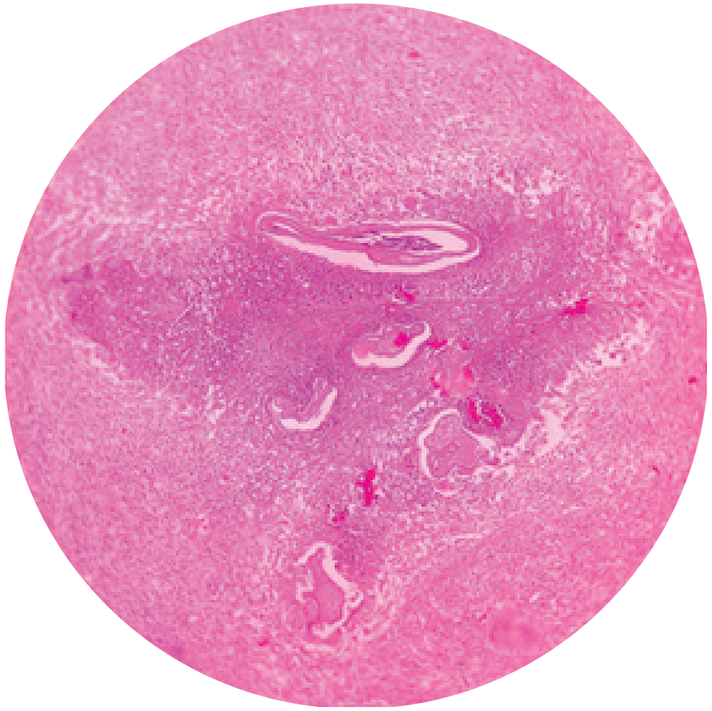

Fig 4. Filarial body with necro-inflammation (H & E 100X)

Discussion

In India, > 98% cases of Filariasis are caused by Wuchereriabancrofti(3).

Eastern Uttar Pradesh and Bihar are the most important zones in India that are endemic for lymphatic Filariasis. In this case, patient was from Purulia district of West Bengal where again Filariasis is seen commonly.

Genital manifestations of lymphatic Filariasis are generally asymptomatic, but may present with hydrocele, lymph scrotum, genital elephantiasis, lymph varix, and chyluria(3). Testicular involvement in Filariasis is usually secondary to epididymitis. Filarial Epididymo-orchitis may be clinically mistaken for testicular tumor and hence awareness of the clinico-pathological spectrum is critical. High index of suspicion for Filariasis is warranted apart from malignancy in a case of painless, solid intratesticular mass of short duration in young men especially in Filariasis endemic zones.

References

1. Goel, T.C., Goel, A. (2016). Filarial Epididymo-Orchitis. In: Lymphatic Filariasis. Springer, Singapore.
2. World Health Organization. Global programme to eliminate lymphatic filariasis. WHO WklyEpidemiol 2006; 61:395-441.
3. Garg PK, Bhatt S, Kashyap B, George A, Jain BK. Genital filariasis masquerading as testicular torsion. J Vector Borne Dis. 2011; 48:119–121.

2. Superficial myofibroblastoma - Case report of a rare mesenchymal tumour of vulva.

Dr.Anita Shobha Flynn – ZTC – Karnataka & Lab head RRL, Bengaluru

Introduction:

Certain distinctive mesenchymal tumours are known to arise from the vulvovaginal region. These lesions are important to be recognised as they may have histologic similarities but exhibit immunohistochemical variability (1). It is important to distinguish these lesions as some of these entities behave in an aggressive manner (1).

Superficial myofibroblastomas of the lower female genital tract are rare tumours occurring more frequently in the vagina and cervix (2 – 5) and less so in the vulva (3). Superficial myofibroblastoma was first reported in 2001 by Laskin et al (2). Since then, less than 70 known cases have been published in literature (2). To the best of our knowledge, this is the first published case of Vulval Myofibroblastoma in Indian literature which we hereby present.

Case report:

A 42 year old lady presented in the Obstetrics and Gynaecology OPD with a complaint of a swelling on the left labia majora for the last 5 -6 months.

It was painless and gradually increasing in size.

There is no history of any hormonal or non – hormonal drug intake. Pap smear done was negative for intraepithelial lesion or malignancy.

The patient is married with two children (P2+0). Her past medical history and menstrual history is unremarkable.

Physical examination:

- The swelling was around 1* 1 cm in size. The skin surface was erythematous and showed focal superficial ulceration.
- The lesion had well defined borders, was firm in consistency and mildly tender. There was no history of any discharge from the growth.
- Clinical diagnosis of granuloma pyogenicum versus sebaceous cyst was made. Excision biopsy was carried out and specimen was sent for Histopathological examination.

Histopathological examination:

- A skin covered soft tissue bit measuring 1 x 0.6 x 0.5 cm was received in the Histopathology Lab for grossing. Cut section was solid grey white.
- Tissue was processed entirely. Microscopy showed an ulcerated covering of acanthotic stratified squamous epithelium.
- The ulcerated area was covered by granulation tissue and inflammatory exudate. Beneath was seen a poorly circumscribed tumour composed of polygonal to spindle cells with high N: C ratio and moderate amount of eosinophilic cytoplasm.
- Nuclei were pleomorphic with coarse chromatin. Few scattered giant cells were also noted. Mitoses were few (2-3/10 HPF).
- There was no necrosis.
- The tumour was seen infiltrating the lower dermis.
- Few thin-walled blood vessels were seen interspersed in the tumour;no thick-walled vessels seen. Resected margins of specimen were free of tumour.
- A diagnosis of undifferentiated neoplasm was made & immunohistochemistry (IHC) was suggested.

Immunohistochemistry works up:

IHC markers tested were PanCK, SMA, CD34, HMB45, desmin and vimentin. All were negative except desmin and C34, the latter showing patchy positivity. Ki – 67 was positive in 5% of cells. The final diagnosis of superficial myofibroblastoma of labia majora was made. Patient is doing well on follow-up.

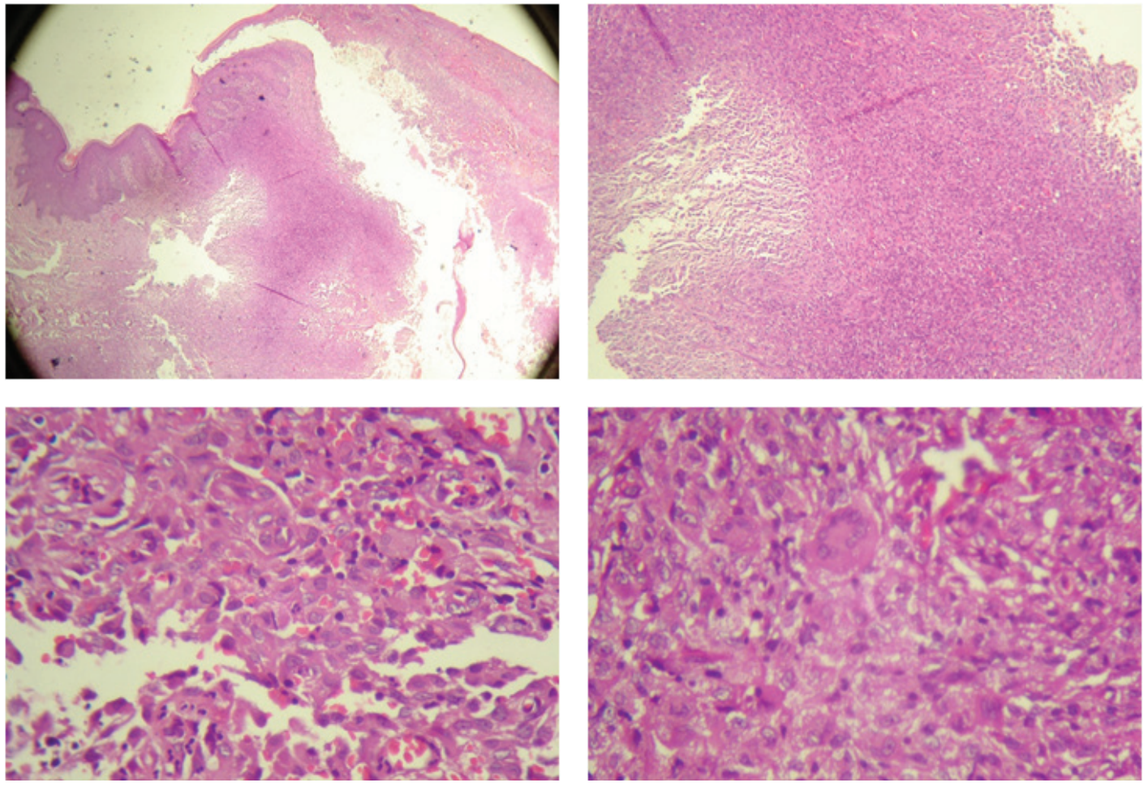

Images (top row) show scanner & low lower view of the tumour. Lower row shows high power view of the tumour.

Discussion:

Laskin et al, in 2001, described a distinctive mesenchymal tumour of lower female genital tract which they called "superficial cervicovaginal myofibroblatoma" (2). Since then, pathologists armed with knowledge of this new entity have been able to ably diagnose these rare tumours. As these tumours were seen to occur more frequently in the vulval and vaginal region than in the cervix, the term "superficial myofibroblastoma of the lower female genital tract" was proposed.

Other tumours arising in the lower female genital tract are aggressive angiomyxoma, superficial angiomyxoma, cellular angiofibroma, angiomyofibroblastoma and fibroepithelial polyps (6). It has been suggested that these, along with superficial myofibroblastoma, are closely related tumours and have a common histogenesis in the female genital tract, possibly from a pluripotential primitive cell located around the vessels of connective tissue (7 – 11).

Superficial myofibroblastoma of the lower genital tract is seen to arise more frequently in the vagina and less so in the vulva (3, 12). Age of presentation ranges from 40 – 77 years. The tumour presents as a polypoid or nodular mass. These tumours are sub-epithelial in location, well circumscribed and range in size from 1 to 6.5cm (12).

Microscopically, the tumours are moderately to highly cellular. Cell types of the tumour are spindle, stellate and rounded cells. A variety of histological patterns have been observed ranging from cells arranged in diffuse sheets to lace- like/ sieve like growth pattern in stroma rich areas and vague pattern in the cellular areas (2).

Mago et al. (12) described three cases where tumour was composed of spindle cells arranged in short fascicles with intervening thick collagen bands, similar to the pattern seen in mammary myofibroblastoma. Another case was described (12) which was composed of uniformly packed rounded cells that on low magnification looked like a "malignant small round blue cell tumours". Few cases have exhibited blood vessels with conspicuous perivascular hyalinization (12). In all the cases cells have bland nuclei with rare, if any, mitoses.

Superficial myofibroblastoma of lower female genital tract raises difficult problems of differential diagnosis with other mesenchymal lesions in this region.

STUDY	CD 34	VIMENTIN	DESMIN	CD99	Bcl- 2	S-100	SMA	HMB-45	CK	ER	PR
STUDY	CD 34	VIMENTIN	DESMIN	CD99	Bcl- 2	S-100	SMA	HMB-45	CK	ER	PR
Laskin et al.	+		+	NA	NA	-	+	NA	-	+	+
CJ Stewart et al.	+	+	+	+	+	-	NA	NA	-	+	+
Magro et al.	+/-	+	+	+/-	+/-	NA	-	NA		+/-	+/-
Our case	-	+	-	NA	NA	NA	-	-	-		

Table 1: IHC pattern seen in various studies diagnosing myofibroblastoma of the lower female genital tract.

References:

1) Purnell S, Lam P, Dynell P, Mohamedaly S, Lipscombe C, Naab T et al. The morphologica; and Immunohistochemical features of a Pedunculated Vulvar Angiomyofibroblastoma: A case with Review of Literature. IOSR Journal of Pharmacy 2016; 6(7).

2) Laskini WB, Fetsch JF, Tavassoli FA. Superficial cervicovaginal myofibroblastoma: Fourteen cases of a distinctive mesenchymal tumour arising from the specialized sub-epithelial stroma of the lower female genital tract. Hum Pathol 2001; 32(7): 715-725.

3) Ganesan R, Mc Cluggage WG, Hirschowitz L, Rollason TP. Superficial myofibroblastoma of the lower FGT: report of a series including tumours with a vulval location. Histopathology. 2005; 46 (2): 137-143.

4) Stewart CJR, Amanuel B, Brennan BA, Janjiv S, Rajakaruna R, Wallace s. Superficial cervicovaginal myofibroblastoma: a report of five cases. Pathology 2005; 37 (2): 144-148.

5) Gonzales Martinez MB, Diaz Diaz C, Martinez Alonso MC, Lopez-Anglade Perez JE. Myofibroblastomacervico-vaginal superficial: Presentation de caso y revis de la literature. Rev EspPatol 2005; 38 (3); 183-187.

6) Olinici CD, Crisan D, Zolog A, Puscas M. Vaginal superficial myofibroblastoma. Case report and review of the literature. Romanian Journal of Morphology and Embryology 2007; 48 (2): 165-170.

7) Pitt MA, Roberts IS, A gbamu DA, Eyden BP. The nature of atypical multinucleated stromal cells: a study of 37 cases from differents sites. Histopathology 1993; 23 (2): 137-145.

8) Lindenmayen AE, Miettenan M. Immunophenotypic features of uterine styromal cells: CD 34 expression in endocervical stroma. Virchows Arch 1995; 426 (5): 457-460.

9) Dufan JP, Soulard R, Gros P. Cellular angiofibroma, angiomyofibroblastoma and aggressive angiomyxoma: members of a spectrum of genital stromal tumours. Am Pathol 2002; 22 (3) 241-243.

10) Al- Nafussi AI, Rebello G, Hughes D, Blessing K. Benign vaginal polyps: a histological, histochemical and immunohistochemical stud of 20 polyps with comparison to normal vaginal sub-epithelial layer. Histopathology 1992; 20 (2): 145-150.

11) Alameda F, Munne' A, Baro'T, Iglesias M, Condom E, Lloreta- Trull J, Serrano S. Vulvar angiomyxoma, aggressive angiomyxoma, and angiomyofibroblkastoma: an immunohistochemical and ultrastructural study. UltrastructPathol 2006; 30 (3): 193-205.

12) Magro G, Caltabiano R, Kacerovska D, Vecchio GM, Kazakov D, Michal M. Vulvovaginal myofibroblastoma: expanding the morphological and immunohistochemical spectrum. A clinicopathologic study of 10 cases. Hum Pathol 2012; 43 (2): 243-53.

ARTICLES

3. Cracking the Code: Understanding Serum Cholin esterase Test Results

Dr. Rajesh Battina & Dr. E. Maruthi Prasad
Department of Biochemistry and Immunoassays, Apollo Diagnostics, Global Reference Lab., Balanagar, Hyderabad 500037, India.

1. Introduction:

Cholinesterases are enzymes that are involved in the normal physiology of the nervous system & the neuromuscular unit. There are two separate cholinesterase enzymes in the body:

(1) Acetylcholinesterase, found in RBC's as well as in the lungs, spleen, nerve endings, and the gray matter of the brain, and

(2) Pseudocholinesterase (butyrylcholinesterase), found in the serum as well as the liver, muscle, pancreas, heart, and white matter of the brain. Cholinesterase tests measure the activity of these enzymes (Cholinesterase Tests, 2021).

Acetylcholinesterase is involved in the breaking down acetylcholine, a chemical that helps to transmit signals across nerve endings. A decrease in the activity of the enzyme acetylcholinesterase results in excess acetylcholine at nerve endings. This can lead to overstimulation of nerves within body tissues and organs.

Pseudocholinesterase is involved in processing and metabolizing drugs (Trang & Khandhar, 2023).

The two most common indications for testing activity levels in the blood are:

1. **Organophosphate pesticide exposure**
2. **Inherited pseudocholinesterase deficiency**

2. Why and when to get tested?

- To determine if you have been exposed to and/or poisoned by certain organophosphate chemicals found in pesticides; to monitor cholinesterase levels if you work with pesticides.
- Sometimes to identify individuals with inherited pseudocholinesterase deficiency before they are given anesthesia with the muscle relaxant succinylcholine or to help determine the cause of prolonged apnea after surgical anesthesia.

When to get tested?

- When you have symptoms of pesticide poisoning or on a regular basis when you are at risk of exposure to organophosphates, such as through work in the agriculture industry and/or frequent use of organophosphate insecticides.
- When you or a close relative have experienced prolonged apnea and muscle paralysis after the use of the drug succinylcholine for a surgical operation (Cholinesterase Tests, 2021).

3. Test Preparation Needed?

Preparing for a Serum Cholinesterase Test

- A blood sample is drawn from a vein in your arm. There are no restrictions on having food before this test. However, some other tests might require fasting may be for 2 or more hours wherein you will be advised earlier.
- Before undergoing a serum cholinesterase test, it is important to inform your healthcare provider of any medications or supplements you are taking, as well as any recent exposure to pesticides or nerve agents (Serum Cholinesterase, n.d.).
- In addition, it is recommended to fast for at least 8 hours prior to the test, as certain foods and drinks can affect the accuracy of the results.

4. How is Cholinesterase testing used?

Cholinesterase testing has two main uses:

- It can be used to detect and diagnose organophosphate pesticide exposure and/or poisoning. It may also be used to monitor those who may be at increased risk of exposure to organophosphate compounds, such as those who work in agricultural and chemical industries, and to monitor those who are being treated for exposure. Typically, tests for red blood cell acetylcholinesterase (AChE) and serum pseudocholinesterase (PChE) are used for this purpose.
- It can be used several days prior to a surgical procedure to determine if someone with a history of or family history of post-operative paralysis following the use of succinylcholine, a common muscle relaxant used for anesthesia, is at risk of having this reaction. In these cases, the test for pseudocholinesterase is usually used. A second test, referred to as a dibucaine inhibition test, may be done to help determine the extent to which the activity of the enzyme is decreased (Robb & Baker, 2023).

5. Symptoms that require to get tested for Cholinesterase

- People who work with organophosphate compounds in the farming or chemical industries may be routinely monitored to assess any adverse exposure, once baseline levels have been established. Cholinesterase testing can also be used to assess any acute exposure to these compounds, which can cause neuromuscular damage. Toxicity can follow a rapid absorption of the compound in the lungs, skin, or gastrointestinal tract. The symptoms of toxicity are varied depending on the compound, quantity, and the site of exposure (Balali-Mood et al., 2012). Early symptoms may include:
- apnea after the use of succinylcholine for anesthesia during an operation. Headache, dizziness
- Nausea
- Excessive tearing in the eyes, sweating and/or salivation
- As the effects of the poisoning worsen, some additional symptoms may appear:
- Vomiting, diarrhea
- Dark or blurred vision due to constricted pupils
- Muscle weakness, twitching, lack of coordination
- Slowed breathing leading to respiratory failure, requiring lifesaving ventilation
- In serious cases, seizures, coma, and death
- Pre-operative screening for pseudocholinesterase activity is advised if a person or a close relative has experienced prolonged paralysis and

6. Test results and monitoring

a. In monitoring for occupational pesticide exposure

Following exposure to organophosphate compounds, AChE, and PChE activity can fall to about 80% of normal before any symptoms occur and drop to 40% of normal before the symptoms become severe (Cholinesterase Tests, 2021). Those who are regularly exposed to these compounds may be monitored for toxic exposure by establishing a baseline activity level and then testing on a regular basis to watch for a significant reduction in the activity of acetylcholinesterase or pseudocholinesterase (Balali-Mood et al., 2012).

b. In testing for acute pesticide exposure/poisoning

Significantly decreased cholinesterase activ ity levels usually indicate excessive absorption of organophosphate compounds. Pseudocholinesterase and RBC acetylcholinesterase activity is usually decreased within a few minutes to hours after exposure. Pseudocholinesterase activity may regenerate in a few days to weeks, while acetylcholinesterase activity will remain low for as long as one to three months. Both plasma and RBC activities are immediately affected by pesticide exposure but, upon removal from exposure, AChE and PChE regenerate at different rates since AChE is produced in blood cells, which have a lifespan of 120 days, whereas PChE is produced in the liver, with a half-life of about two weeks (Peter et al., 2014).

c. In testing for succinylcholine sensitivity

About 3% of people have low activity levels of pseudocholinesterase due to an inherited deficiency and will have prolonged effects from the muscle relaxant succinylcholine. Total quantitative pseudocholinesterase levels will be evaluated prior to surgery for patients with a history or family history of prolonged apnea after the use of this drug. Low activity levels of pseudocholinesterase levels indicate that these people may be at increased risk of experiencing prolonged effects of the muscle relaxant. A second test, the dibucaine inhibition test, may also be performed to help characterize the degree of a person's sensitivity to the drug. The lower the result from a dibucaine inhibition test, the greater the risk of drug sensitivity (Trujillo & West, 2023).

Reduced cholinesterase levels can also be caused by chronic liver disease and malnutrition. Total cholinesterase activity can be lowered in a number of other conditions, including pregnancy, renal disease, shock, and some cancers (Cholinesterase Tests, 2021).

7. Discussion

A serum cholinesterase test is a blood test that measures the level of cholinesterase in the blood. Cholinesterase is an enzyme that is found in various tissues and organs in the body, including the liver. The test is commonly used to monitor individuals who have been exposed to pesticides or nerve agents, as these substances can inhibit the activity of cholinesterase in the body (Trueblood et al., 2019).

Interpreting Serum Cholinesterase Test Results: The normal range for serum cholinesterase levels is between 5.90-12.22 U/mL. If the levels fall below this range, it may indicate that the individual has been exposed to a substance that inhibits cholinesterase activity.

We received a batch of 100 samples for the cholinesterase test from Apollo RRL, Kolkata. Among the 100 samples for serum cholinesterase levels from Kolkata, 25 samples had lower values. The cholinesterase was measured using a VITROS CHE slide by measuring the rate of change and reflection density (at 400nm) in the VITROS-4600 machine. All the samples with lower value were from Kolkata and the patients from whom these samples were drawn worked in the pharmaceutical industry and were exposed to methanol and anticancer drugs/raw materials.

The lower levels of cholinesterase could be due to prolonged exposure to organophosphates, pesticides, methanol, ethanol, or spray paintings, HCl, and caustic sodas. Table 1 represents the patients' age and cholinesterase levels.

Table 1: Age and Cholinesterase levels (Bio reference range 5.90-12.22 U/mL).

S No	Age (years)	Cholinesterase (U/mL)
1.	46	5.4
2.	35	4.7
3.	50	5.5
4.	52	4.9
5.	29	5.8
6.	48	5.7
7.	48	4.2
8.	39	5.5
9.	40	5.6
10.	41	2.6
11.	29	5.5
12.	39	4.7
13.	48	5.8
14.	44	5.6
15.	38	5.4
16.	49	5.6
17.	45	5.1
18.	43	4.3

S No	Age (years)	Cholinesterase (U/mL)
19.	36	5.1
20.	51	5.7
21.	34	4.8
22.	34	5.3
23.	29	4.5
24.	47	5.5
25.	36	5.2

However, it is important to note that low cholinesterase levels can also be caused by other factors, such as liver disease or genetic disorders. Therefore, it is important to consider all relevant factors when interpreting test results.

Serum cholinesterase test is a relatively safe procedure, but there are some potential risks and complications associated with it. These include bleeding, infection, and bruising at the site where the blood is drawn.

In rare cases, some individuals may experience dizziness or fainting during the procedure. If someone unexpectedly has prolonged apnea after surgery, testing for succinylcholine sensitivity may be performed; however, the sample should be obtained after 24 to 48 hours have elapsed following the surgery to avoid interference by any drugs given during the surgery that could affect the results. It is important to inform your healthcare provider if you experience any unusual symptoms during or after the test.

8. Concluding remarks

The serum cholinesterase test is a valuable tool for monitoring individuals who have been exposed to pesticides or nerve agents. This test is conducted to diagnose or rule out the following possibilities poisoning due to organophosphate compounds before surgical procedure to avoid post-surgery paralysis, neuromuscular damage, chronic liver disease, and malnutrition cancer. However, as per the data on people exposed to industrial chemicals, it is shown that nearly 25% are deficient in cholinesterase levels, and it is important to interpret the results carefully and consider all relevant factors before making any conclusions. By following proper preparation and care procedures, individuals can minimize the potential risks and complications associated with the test and ensure accurate results. **Not every laboratory will offer this testing. It may be necessary to send the sample collected to a reference laboratory (Example: Apollo Global Reference Lab, Hyderabad).**

9. References

1. Balali-Mood, M., Balali-Mood, K., Moodi, M., & Balali-Mood, B. (2012). Health Aspects of Organophosphorous Pesticides in Asian Countries. Iranian Journal of Public Health, 41(10), 1–14.
2. Cholinesterase Tests. (2021, March 25). Testing.Com. https://www.testing.com/tests/cholinesterase-test/
3. Peter, J. V., Sudarsan, T. I., & Moran, J. L. (2014). Clinical features of organophosphate poisoning: A review of different classification systems and approaches. Indian Journal of Critical Care Medicine : Peer-Reviewed, Official Publication of Indian Society of Critical Care Medicine, 18(11), 735–745. https://doi.org/10.4103/0972-5229.144017
4. Robb, E. L., & Baker, M. B. (2023). Organophosphate Toxicity. In StatPearls. StatPearls Publishing. http://www.ncbi.nlm.nih.gov/books/NBK470430/

   Serum Cholinesterase. (n.d.). Ucsfhealth.Org. Retrieved May 22, 2023, from https://www.ucsfhealth.org/Medical Tests/003358
5. Trang, A., & Khandhar, P. B. (2023). Physiology, Acetylcholinesterase. In StatPearls. StatPearls Publishing. http://www.ncbi.nlm.nih.gov/books/NBK539735/
6. Trueblood, A. B., Ross, J. A., Shipp, E. M., & McDonald, T. J. (2019). Feasibility of Portable Fingerstick Cholinesterase Testing in Adolescents in South Texas. Journal of Primary Care & Community Health, 10, 2150132719838716. https://doi.org/10.1177/2150132719838716
7. Trujillo, R., & West, W. P. (2023). Pseudocholinesterase Deficiency. In StatPearls. StatPearls Publishing. http://www.ncbi.nlm.nih.gov/books/NBK541032/

4. Safe Diagnostics: Navigating the Testing Terrain

Dr. E. Maruthi Prasad1, Narendra Vadlamudi[2]

[1]Consultant biochemist, Department of Biochemistry and Immunoassays, Apollo Diagnostics, Global Reference Lab, Hyderabad 500037, Telangana, India.

[2]Business Quality Lead, Apollo Diagnostics, Global Reference Lab, Hyderabad 500037, Telangana, India.

1. Introduction:

Patient safety is a critical aspect of diagnostics and testing in healthcare. It involves the prevention of harm to patients during the provision of medical care (1). Diagnostic tests play a crucial role in identifying health conditions, but they can also pose risks to patients if not performed properly (2).

Due to instances of patient safety being compromised within medical facilities, a new discipline called patient safety has emerged. The purpose of this discipline is to minimize the chances of risks and errors that could result in harm to patients who are receiving health care. The bedrock of this discipline lies in its ability to continuously improve by learning from errors and adverse events (1).

2. Importance of Patient Safety in Diagnostics and Testing

Patient safety is a fundamental principle of healthcare that should be applied to all aspects of medical care, including diagnostics and testing. Patients have the right to receive safe and effective care, and it is the responsibility of healthcare providers to ensure that their patients are protected.

Diagnostic tests are essential tools for identifying health conditions and guiding treatment decisions. However, these tests can also cause harm to patients if they are not performed correctly or if the results are misinterpreted. Therefore, ensuring patient safety is crucial when administering diagnostic tests (2).

3. Potential Risks Associated with Diagnostics and Testing

The promotion of key strategic areas to improve global patient safety has been significantly advanced by the efforts of the Patient Safety and Risk Management Unit at WHO. Promoting collaboration among member states and other stakeholders while providing global leadership. To set global priorities for action by developing guidelines and tools. Technical support is provided to build the capacity of Member States to engage patients and families for safer healthcare and monitor improvements in patient safety.

Diagnostics and testing carry several potential risks that can compromise patient safety. One of the most significant risks is misdiagnosis or delayed diagnosis, which can result in incorrect treatment and worsen the patient's condition. Other risks include exposure to adverse reactions to contrast agents, and infections from invasive procedures (3).

Another risk associated with diagnostics and testing is the potential for errors in test results interpretation. These errors can lead to incorrect diagnoses, unnecessary treatments, and patient harm. Therefore, it is essential to ensure that diagnostic tests are performed accurately and that the results are interpreted correctly (2).

4. Strategies for Mitigating Risks in Diagnostics and Testing

To ensure patient safety in diagnostics and testing, healthcare providers must implement strategies to mitigate potential risks. One strategy is to use evidence-based guidelines and protocols for performing diagnostic tests. These guidelines help ensure that tests are performed safely and effectively, reducing the risk to patients.

Another strategy is to improve communication and collaboration among healthcare providers involved in the diagnostic process. Effective communication can help prevent errors in test results interpretation and ensure that patients receive appropriate follow-up care based on their test results (4).

5. Patient Education and Informed Consent

Patient education and informed consent are essential components of patient safety in diagnostics and testing. Patients have the right to be informed about the risks and benefits of diagnostic tests and to provide informed consent before undergoing any procedure [5].

Healthcare providers must also educate patients about how to prepare for diagnostic tests, what to expect during the procedure, and what the results mean. This information can help patients feel more comfortable and confident about the process and reduce the risk of errors or misunderstandings (2).

To guarantee the success of patient safety strategies, it is imperative to have clear policies along with strong leadership capacity and skilled healthcare professionals on board. Additionally, it's important to collect data that drives improvement in the field while simultaneously involving patients in their own care (6).

6. Discussion and Conclusion

Key action areas

There are various areas in the diagnostic process where patient safety may be compromised, including specimen collection, transportation, handling, storage, and analysis. Each of these areas needs to be managed appropriately to ensure that the patient's well-being is not compromised (Figure 1).

Figure 1. Key strategies of patient safety for high-quality healthcare.

Quality in healthcare can only be achieved if patient safety is regarded as a fundamental aspect, and a clear consensus exists worldwide regarding the need for high-quality healthcare to prioritize effectiveness and safety while keeping in mind patients' requirements. Equitable distribution of integrated and timely health service facilities along with efficiency is essential for reaping benefits from quality healthcare (7).

By targeting the system that allows harm, we can begin making improvements by making an environment that is open and transparent with a prevailing safety culture is necessary.

Ensuring patient safety is a fundamental aspect and it involves minimizing the risk of harm to patients during their medical care journey. This requires a multidisciplinary approach that includes healthcare professionals, patients, and their families. Patient safety measures include identifying and addressing potential risks, implementing effective communication strategies, and promoting a culture of safety (1). One of the most important considerations in patient safety in diagnostics is the accuracy and reliability of test results. Diagnostic tests must be performed and interpreted accurately.

- Another crucial aspect of patient safety in diagnostics is ensuring that the correct patient is identified, and their test results are accurately labelled.
- Making sure that the appropriate test is ordered for the correct patient is critical in ensuring that the patient receives the correct diagnosis and treatment.
- It is also important to maintain the privacy and confidentiality of patient information throughout the total testing process.
- This includes not only the results of the tests but also the patient's personal information, such as their name, address, and other identifying data.

To ensure patient safety in diagnostics, healthcare personnel must undergo comprehensive training on the proper procedures for specimen collection, handling, and transportation. There should also be a comprehensive quality assurance system in place to ensure that all diagnostic tests are accurate and reliable. Patient safety in diagnostics also involves effectively communicating test results to the patient and their healthcare provider promptly (2). This includes conveying the findings of the tests, interpreting the results, and providing guidance regarding the interpretation and the next steps of the diagnostic process.

By using evidence-based guidelines, improving communication and collaboration among healthcare providers, and educating patients about the risks and benefits of diagnostic tests, we can ensure that patients receive safe and effective care (8).

Investing in increasing patient safety can lead to noteworthy financial benefits as well as improved results for patients (1). Reducing the burden of harm by up to 15% is possible through engaging patients as a prevention measure when done effectively. Ultimately, patient safety in diagnostics and testing is essential for providing high-quality healthcare and improving patient outcomes.

In conclusion, patient safety in diagnostics is critical to ensuring that patients receive the best possible care. This includes maintaining the accuracy and reliability of diagnostic tests, ensuring that the correct tests are ordered for the correct patient, maintaining the privacy and confidentiality of patient information throughout the diagnostic process, and effectively communicating test results to the patient and healthcare provider. Achieving these goals requires comprehensive training, quality assurance systems, and effective communication throughout the diagnostic process.

7. References

[1] "Patient Safety." https://www.who.int/news-room/fact-sheets/detail/patient-safety (accessed May 24, 2023).

[2] E. P. Balogh et al., "The Diagnostic Process," in Improving Diagnosis in Health Care, National Academies Press (US), 2015. Accessed: May 24, 2023. [Online]. Available: https://www.ncbi.nlm.nih.gov/books/NBK338593/

[3] E. P. Balogh et al., "Overview of Diagnostic Error in Health Care," in Improving Diagnosis in Health Care, National Academies Press (US), 2015. Accessed: May 24, 2023. [Online]. Available: https://www.ncbi.nlm.nih.gov/books/NBK338594/

[4] K. K. Hall et al., "Diagnostic Errors," in Making Healthcare Safer III: A Critical Analysis of Existing and Emerging Patient Safety Practices [Internet], Agency for Healthcare Research and Quality (US), 2020. Accessed: May 24, 2023. [Online]. Available: https://www.ncbi.nlm.nih.gov/books/NBK555525/

[5] P. Shah, I. Thornton, D. Turrin, and J. E. Hipskind, "Informed Consent," in StatPearls, Treasure Island (FL): StatPearls Publishing, 2023. Accessed: May 24, 2023. [Online]. Available: http://www.ncbi.nlm.nih.gov/books/NBK430827/

[6] "Tools and Strategies for Quality Improvement and Patient Safety - Patient Safety and Quality - NCBI Bookshelf." https://www.ncbi.nlm.nih.gov/books/NBK2682/ (accessed May 24, 2023).

[7] C. L. Seelbach and G. D. Brannan, "Quality Management," in StatPearls, Treasure Island (FL): StatPearls Publishing, 2023. Accessed: May 24, 2023. [Online]. Available: http://www.ncbi.nlm.nih.gov/books/NBK557505/

[8] M. O'Daniel and A. H. Rosenstein, "Professional Communication and Team Collaboration," in Patient Safety and Quality: An Evidence-Based Handbook for Nurses, R. G. Hughes, Ed., in Advances in Patient Safety. Rockville (MD): Agency for Healthcare Research and Quality (US), 2008. Accessed: May 24, 2023. [Online]. Available: http://www.ncbi.nlm.nih.gov/books/NBK2637/

5. Riddles & Quiz: Epithelium

Dr. Marquess Raj & Dr.Shalini Singh - Co-editors AD express

Epithelium or epithelial tissue is ubiquitous in human tissue. Epithelial cells line the outer surfaces of organs and blood vessels throughout the body, as well as the inner surfaces of cavities in many internal organs. An example is the epidermis which is composed of stratified squamous cells, the outermost layer of the skin.

There are three principal shapes of epithelial cell: squamous, columnar, and cuboidal. These can be arranged in a singular layer of cells as simple epithelium, either simple squamous, simple columnar, or simple cuboidal, or in layers of two or more cells deep as stratified (layered), Epithelial cells possess gap junctions and are aligned perpendicularly to a basement membrane.

Chronic irritation can induce a change called metaplasia wherein one type of epithelium changes into another type which is normally found elsewhere. This change is called metaplasia. The quintessential example being Barrett's esophagus, wherein the squamous epithelium changes to columnar epithelium when chronically irritated by acid reflux.

Match of the following riddles to the correct epithelium

1. Pavement like, flat as pancakes	A. Transitional
2. Tall in stature possess fine hairs	B. Cuboidal
3. Top layer cells are rounded	C. Pseudo stratified
4. Like a stack of boxes	D. Columnar
5. Nuclei not in a regular row	E. Squamous

Answers to the pervious quiz in the June23 issue:
The appropriate 'markers' are matched with eosinophil featuring twice).

1. Filariasis	A. Eosinophilia
2. Elevated IgE	B. Eosinophilia
3. Supravital staining	C. Reticulocytes
4. Typhoid	D. Leukopenia
5. Toluidine blue	E. Basophil

6. Quiz - – Know your moulds: An example from the ear

Dr.Mir Salman Ali – Head of Microbiology, Global reference laboratory, Hyderabad

Identify the fungus shown below amidst fibro collagenous tissue, from an ear biopsy sample. A brief of the same shall be given in the next issue.

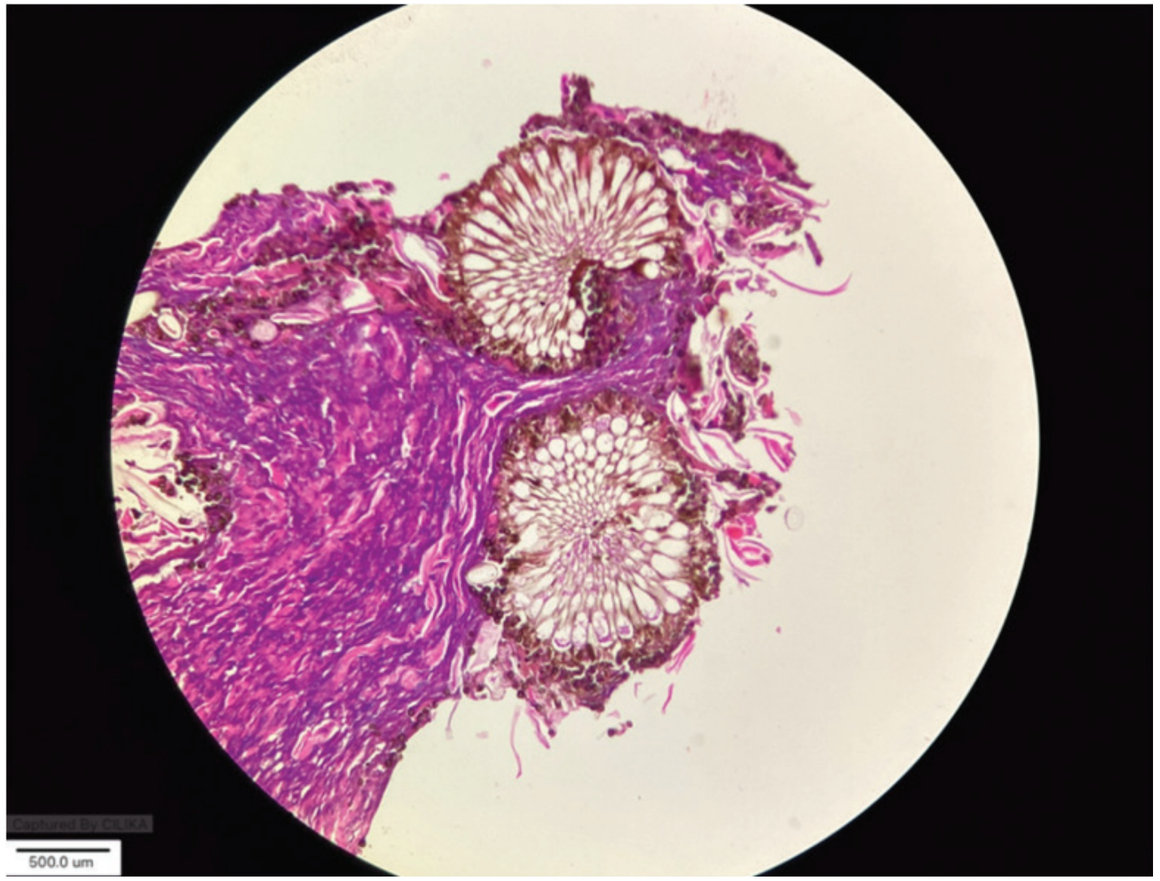

Answer to identify the crystal in the April issue: Ammonium biurate crystals

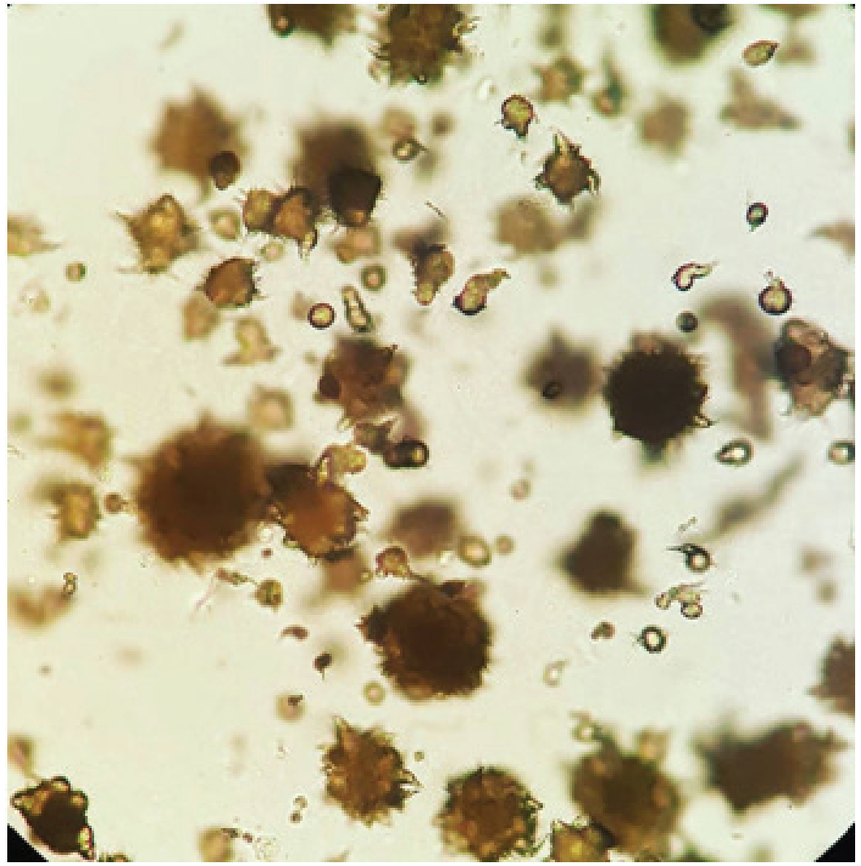

Clinical Significance:

Ammonium biuratecrystals generally appear as brown or yellow-brown spherical bodies with irregular spikes (“thorn-apples”). In some urine samples, they do not have irregular protrusions but have smooth borders and can resemble calcium carbonate.

Though possible in urine of any pH, their formation is favoured in neutral to acidic urine. They are frequently seen with amorphous urates. These crystals are noted in conditions wherein there is high protein breakdown such as chemotherapy.

Fun fact: They can be seen in urine from normal Dalmatians &English Bulldogs

CME and Conferences Conducted

CME in Association with Indian Academy of Paediatrics in Warangal

CME in Association with IMA (INDIAN MEDICAL ASSOCIATION) and PCSC (PONDY CANCER SPECIALITY CENTER) in Pondicherry

Pondicherry CME

CME in Association with BSOG (Bangalore Society of Obstetrics and Gynaecology) in Bangalore

HOSPICON Conference in Thane

CME in Association with Apollo Fertility in Chennai

Apollo DIAGNOSTICS®

Expertise. Empowering you.