

AD Express

August 2023

On The aRight Track, For Precise Results

Dr. Ramesh Kinha
M.D (Pathology)

GM - Technical

Dr. Anita Flynn
M.D (Pathology)

ZTC - Karnataka

Dr. Abhik Banerjee
M.D (Pathology)

ZTC - West Bengal & East Zone

Dear Reader, Many parts of the country receive showers in August & water borne illnesses are expected to rise in the monsoon season. We request our readers to avoid wading through stagnant water & take precautions to brace against monsoon related diseases.

We also take this opportunity to thank all our patrons for the immense support we have garnered over the years. We will continue to encourage contributors to write on their experiences & share their expertise.

In this fifth edition of the year, we share an interesting repertoire of topics. Our first case report is as esoteric as it gets, we share findings from an interesting fetal autopsy. Bone & soft tissue tumors can pose significant diagnostic challenge & we share a 'histopathology' entity from the bone realm that presented with different clinical scenarios.

Astute judgment & robust background of the role played by the various factors that take part in the coagulation 'concert' underlines the approach to be taken while investigating hypercoagulable disorders. The first article details the same. Our second article throws light on viral carcinogenesis, deviating from the molecular perspective & embracing it from a literary standpoint.

We have introduced another dimension to our quizzes by introducing 'know your cell / crystal / moulds etc.' A strong background of cell morphology will augur good for any laboratory & a quiz on the above lines will help technologists appreciate

morphology better. We expect our creative tendencies to gravitate towards biochemistry ballads, serology sonnets & musings from microbiology in the forthcoming issues.

We thank the contributors for taking time to put pen to paper & covering a gamut of topics with aplomb. AD express has gained considerable impetus by the way of your contributions & we welcome more from you all. Also humbly request you to share your feedback on 'AD express & we assure you that feedback from you will make each next issue ever more interesting!

Wishing you all a happy reading & a great year ahead!

Best regards,

Dr. Marquess Raj M.D. Dip. N.B (Path), MBA (HM)

ZTC - TN & Pondicherry
marquess.raj@apolloclonics.in

Dr. Shalini Singh M.D (Path), IFCAP, DMSC (Endocrine)
Lab Director, Global reference lab, Hyderabad

shalini.singh@apolloclicnic.com



Case reports :-

1. A Novel Association of Bilateral Multicystic Renal Dysplasia with Hirschsprung Disease.

Dr. Kavitha Bali N, Dr. A Kalyan Rao, Dr. A Ramakrishna Reddy, Dr. Ankita Pal Singh, Dr. Shalini Singh - Department of Histopathology, Apollo Diagnostics GRL, Hyderabad, TS, India

PAGE - 1

2. Revisiting 2 cases of non-ossifying fibroma - Pearls & potential pitfalls.

Dr.V.Kalyan Chakravarthy - ZTC - Andhra Pradesh & Lab head RRL, Vijayawada, Dr.Marquess Raj - ZTC - Tamilnadu & Pondicherry & Dr.Chidambharam C - Consultant Histopathologist, Chennai.

PAGE - 4

Articles

3. Diagnostic workup for hypercoagulable disorders.

Dr. Shalini R. Consultant Pathologist, Department of Hematology and Clinical Pathology, Apollo Diagnostics GRL, Hyderabad.

PAGE - 10

4. Viral carcinogenesis - A spell the awakens an old genie from the new bottle

Dr. Marquess Raj - ZTC - Tamil Nadu & Pondicherry

PAGE - 15

5. Quiz - Sleuthing with a semen sample

Dr. Marquess Raj - Co-editor AD express

PAGE - 17

6. Quiz - Know your moulds - An example from the ear

Dr. Mir Salman Ali - Head of Microbiology, Global reference laboratory, Hyderabad

PAGE - 18

7. CME and Conferences

PAGE - 20

CASE REPORT

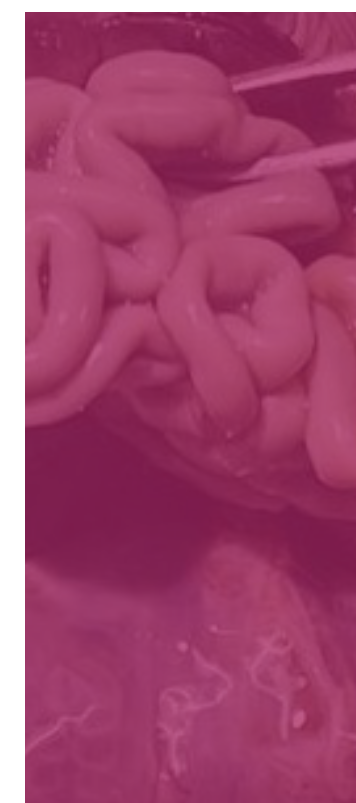
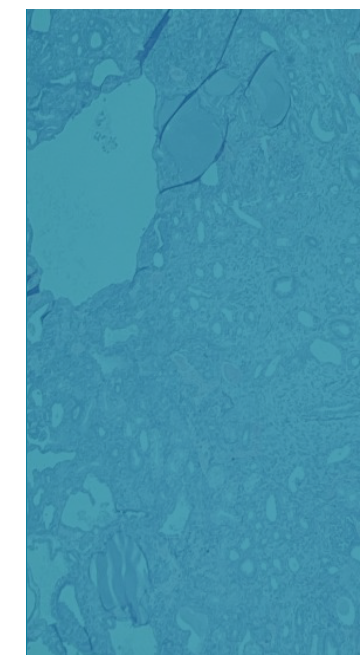
1. A Novel Association of Bilateral Multicystic Renal Dysplasia with Hirschsprung Disease

Dr. Kavitha Bali N, Dr A. Kalyan Rao, Dr. A Ramakrishna Reddy, Dr. Ankita Pal Singh, Dr. Shalini Singh, Department of Histopathology, Apollo Diagnostics GRL, Hyderabad, TS, India

Introduction:

Intrauterine fetal demise (IUFD) can occur due to multiple factors, the common etiologies' being maternal factors, placental abnormalities or fetal anomalies. Most common causes of IUFD in first and early second trimester are most often due to congenital anomalies. One of the common congenital anomalies is the congenital anomalies of the kidneys or lower urinary tract (CAKUT), encompassing various developmental malformations including Multicystic renal dysplasia (MCD), which can occur in isolation or in combination with other syndromes.

Hirschsprung's disease (HD) is a multifactorial disorder with involving over 20 genes, associated with heterogeneous genetic pathways which can occur in isolation (70%) or in association with other chromosomal abnormalities, in which almost all organs and tissues in the body may be involved. Based on literature review and cohort study, an association between HD and CAKUT has been found to be present in almost 1/5th of the patients with HD.



Case report:

We present a case of aborted male fetus of around 20 weeks of gestation submitted for partial medical autopsy, received in 10% neutral buffered formalin. Fetal grossing was done according to a set protocol. External findings were mostly unremarkable, except for imperforate anus. Development and morphometry were appropriate for age. On opening the abdomen, there were enlarged and separately situated bilateral kidneys with external surface showing multiple small translucent cysts. There was no evidence of horseshoe kidney or dilated ureters. Further grossing revealed distal colon and proximal rectal dilatation. Rest of the bowel was found to be unremarkable grossly. Gross and microscopic examination of other viscera like lungs, heart, stomach, urinary bladder, pancreas, genitalia and brain were unremarkable. Histopathological sections taken from bilateral kidneys show multiple thin-walled cysts of varying sizes lined by flattened to cuboidal epithelium. Immature collecting ducts with fibromuscular collars were noted, along with primitive glomerular structures. These features are consistent with Multicystic renal dysplasia. Sections from the narrowed segment of proximal rectum showed preserved mucosa, with absence of ganglion cells in the submucosa and muscularis propria, which lead to the final diagnosis of bilateral Multicystic renal dysplasia associated with Hirschsprung disease.

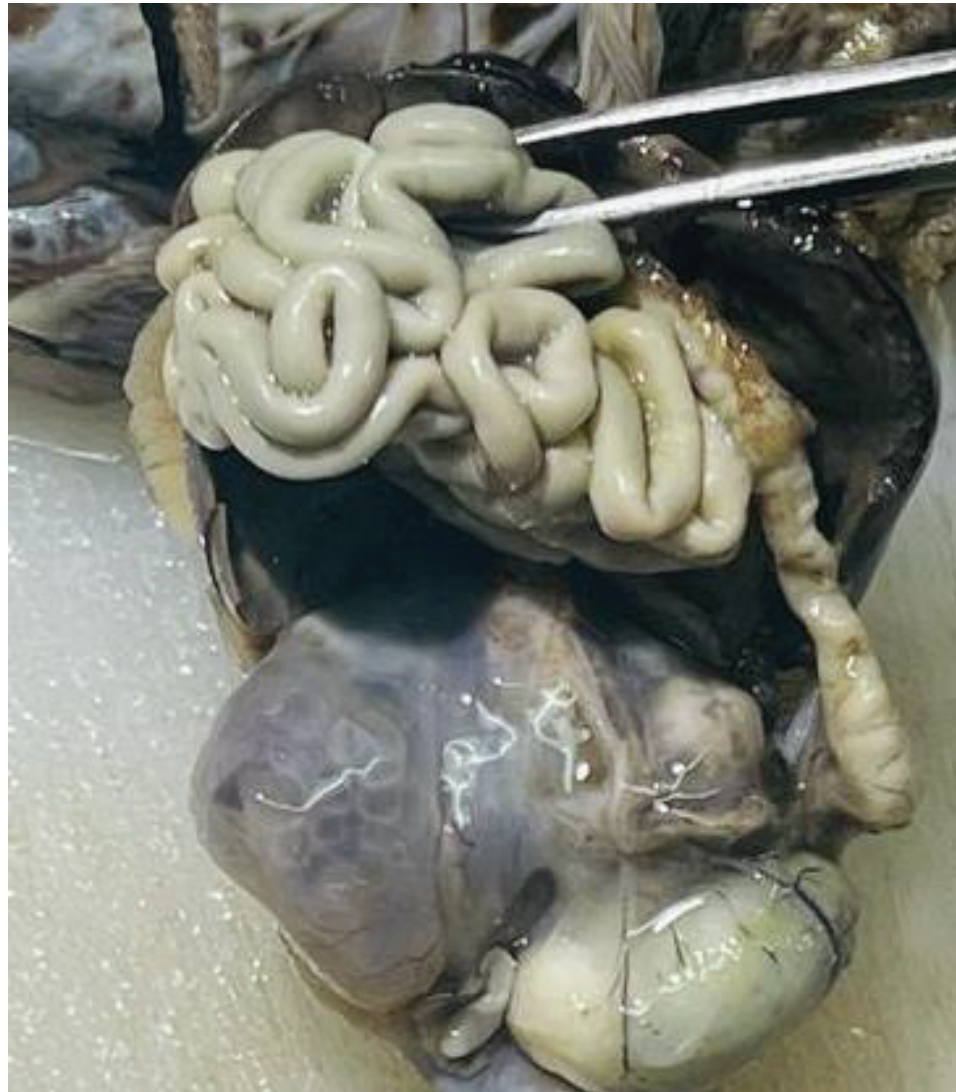

Figure 1: Bilateral kidneys (black arrows) enlarged with multiple tiny translucent cysts, dilated distal colon (red arrow) and proximal rectum. H&E. 400x

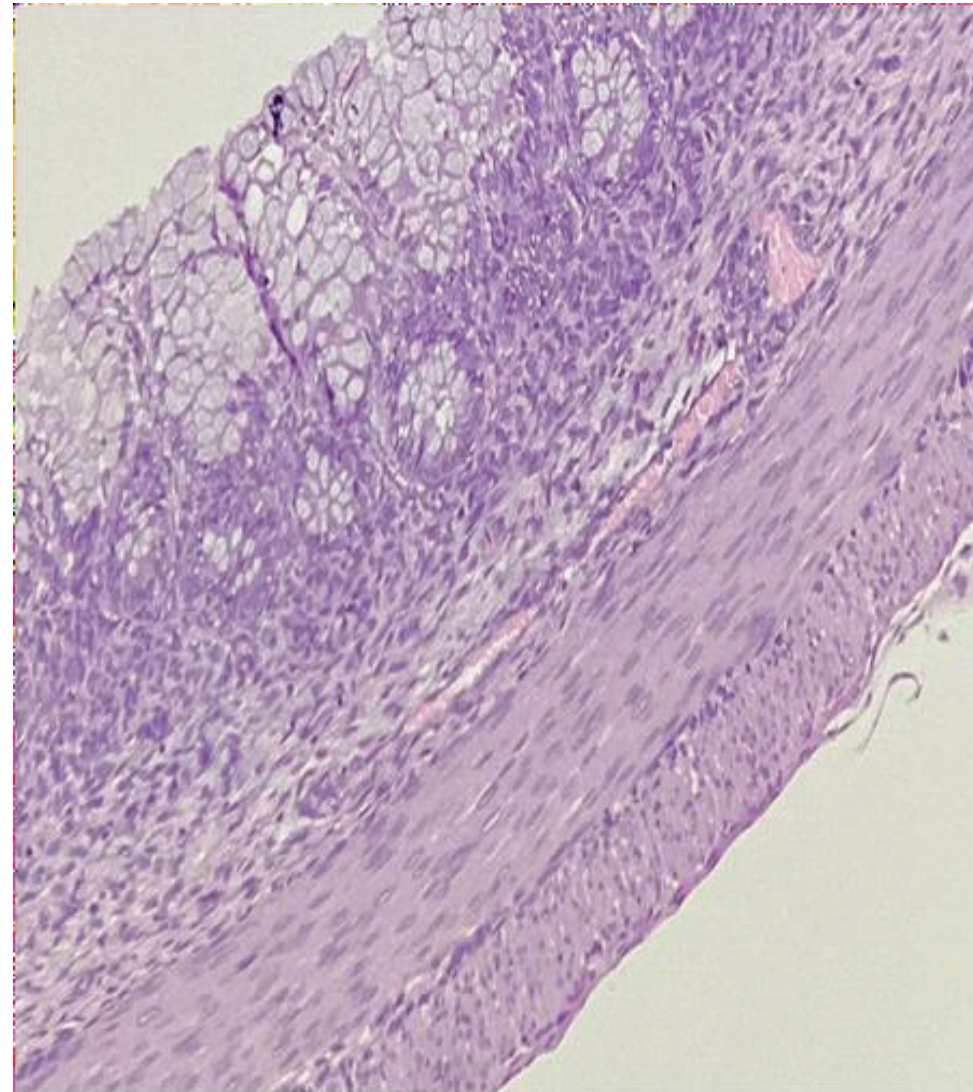


Figure 2: Rectal mucosa showing absence of ganglion cells. H&E. 400x

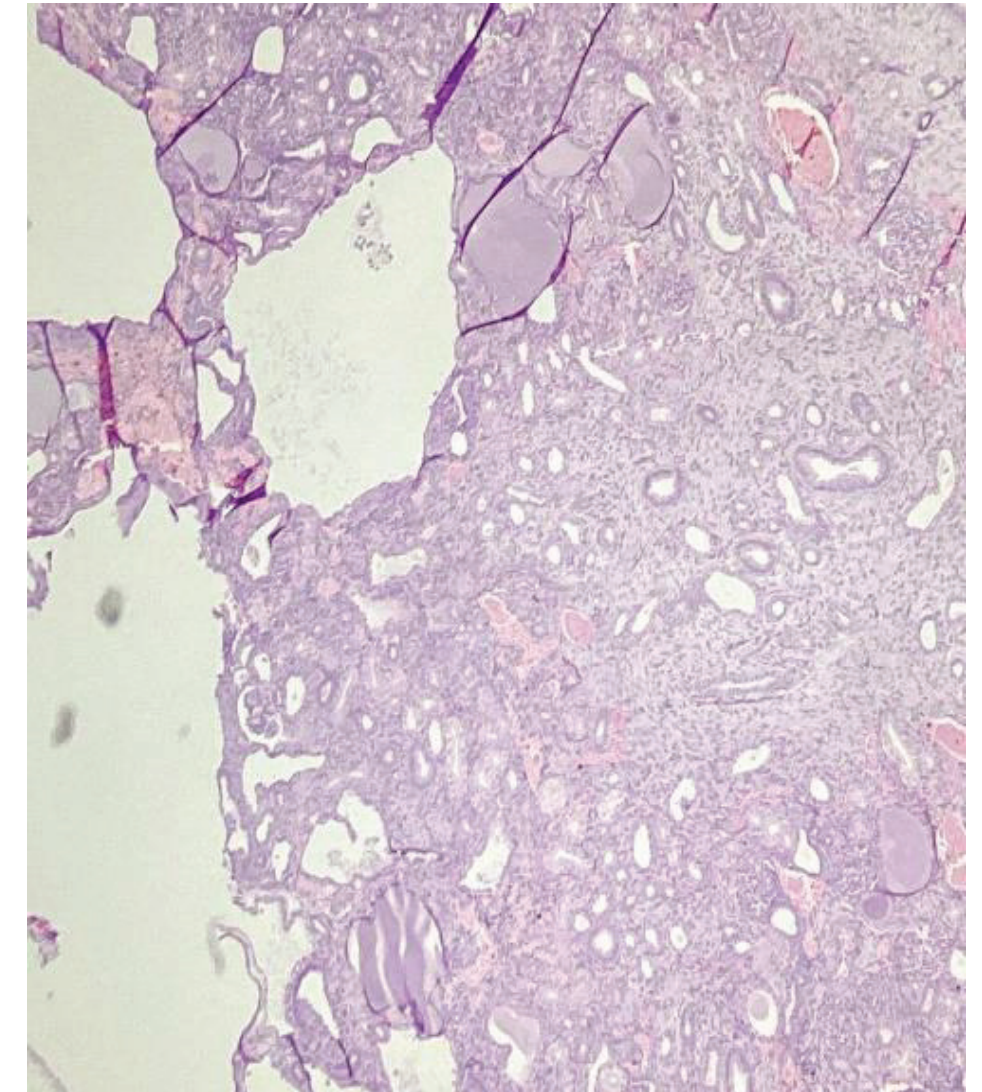


Figure 3: Renal tissue with multiple cystic spaces and disorganized parenchyma. H&E. 400x

Discussion:

CAKUT originates from developmental defects which include renal agenesis, renal hypoplasia, renal dysplasia, supernumerary kidneys, ectopic or fused kidneys, renal duplication, ureteropelvic junction obstruction, primary megaureter/ureterovesical junction obstruction, vesicoureteral reflux, ureteroceles, and posterior urethral valves. Multicystic dysplasia of the kidney is characterized by multiple cysts of varying size in the kidney and the absence of a normal pelvicalyceal system. The affected kidney is non-functional and mostly fatal. HD is defined by the failure of neural crest-derived neuroglial progenitors to colonize the entire length of the intestinal tract, which can occur in isolation, or may occur in association with numerous other syndromes.

There is a prevalence of 9.5 % of HD associated with all forms of CAKUT, but a very low percentage of HD is seen in association with bilateral MCD. The hypothesis of an association between HD and CAKUT, based on common genetic background, may be due to absent expression of RET or GDNF, or with mutations in these genes.

Conclusion:

Hirschsprung disease and Multicystic renal dysplasia are two pathological entities with their own complex genetic background, and could be mutually associated based on a common genetic pathway. Although this association has been described in literature, little is known

regarding its prevalence and clinical relevance. We recommend ultrasound screening of the urinary tract and lower gastrointestinal tract in every antenatal anomaly screening, and meticulous gross examination during fetal autopsy.

References:

- 1) Hirschsprung Disease and Congenital Anomalies of the Kidney and Urinary Tract (CAKUT): a genetic disorder or just a coincidence? Julie Eelen, Marc Miserez, Djalila Mekahli, Ilse Hoffman
- 2) Pini Prato A, Rossi V, Mosconi M, et al. A prospective observational study of associated anomalies in Hirschsprung's disease. Orphanet Journal of Rare Diseases. 2013; 8:184.
- 3) Genetics of Congenital Anomalies of the Kidney and Urinary Tract: The Current State of Play, Valentina P. Capone, William Morello, Francesca Taroni, and Giovanni Montini*, 2017 Apr; 18(4): 796., Int J Mol Sci.

- 4) Congenital Anomalies of the Kidney and the Urinary Tract (CAKUT), Maria M. Rodriguez, 2014 Dec; 33(5-6): 293-320, Fetal Pediatr Pathol.
- 5) Neonatal Hirschsprung disease with Multicystic dysplastic kidneys presenting as multiple gastrointestinal perforations, Verinderjit S Virdi 1, Ajaiwant S Cheema, Trop Gastroenterol, 2003 Apr-Jun;24(2):99-101

2. Revisiting 2 cases of non-ossifying fibroma – Pearls & potential pitfalls.

Dr. V. Kalyan Chakravarthy – ZTC – Andhra Pradesh & Lab head RRL, Vijayawada,
Dr. Marquess Raj - ZTC – Tamil Nādu & Pondicherry & **Dr. Chidambharam C** –
Consultant Histopathologist, Chennai.

Case 1:

A 28 year old man came to neurosurgery OP with the complaint of back ache since 5 months followed by swelling over upper back since 2 months

Swelling is insidious in onset, gradually progressed in size and pain increased since 2 months.

No H/O trauma or fever,
Vitals- Normal.

Rest of the clinical examination was normal

MRI findings:

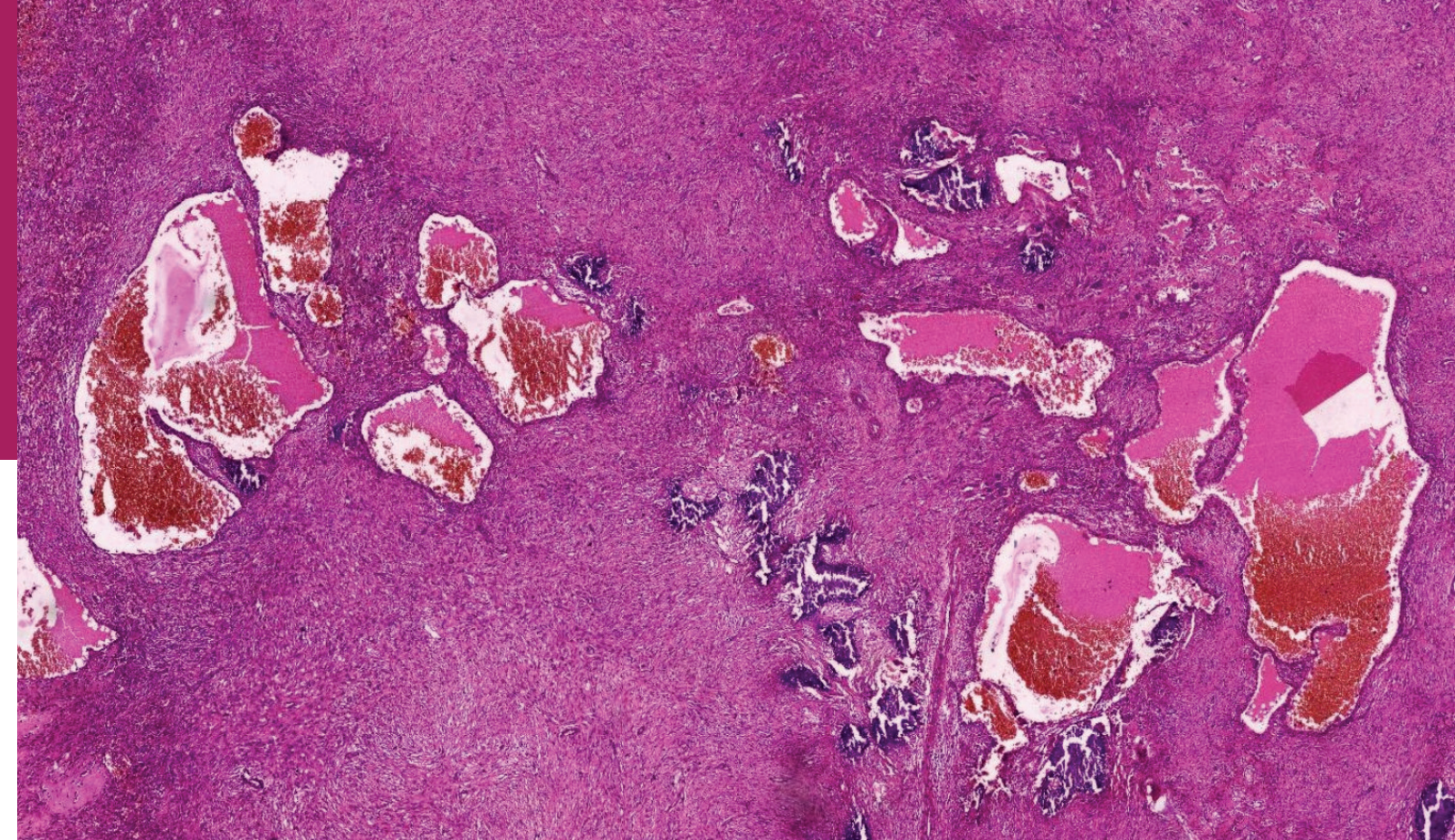
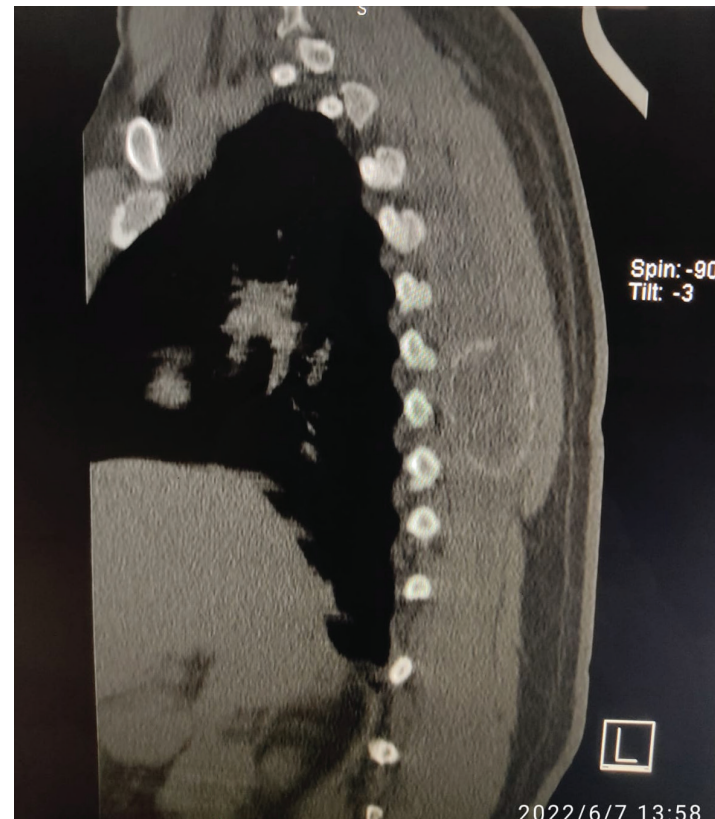
- 4.7x2.8x3.6 cm sized lesion with septae noted. Fluid level in posterior paraspinal muscles at D6-7 level.

Impression: ? Soft tissue Aneurysmal bone cyst

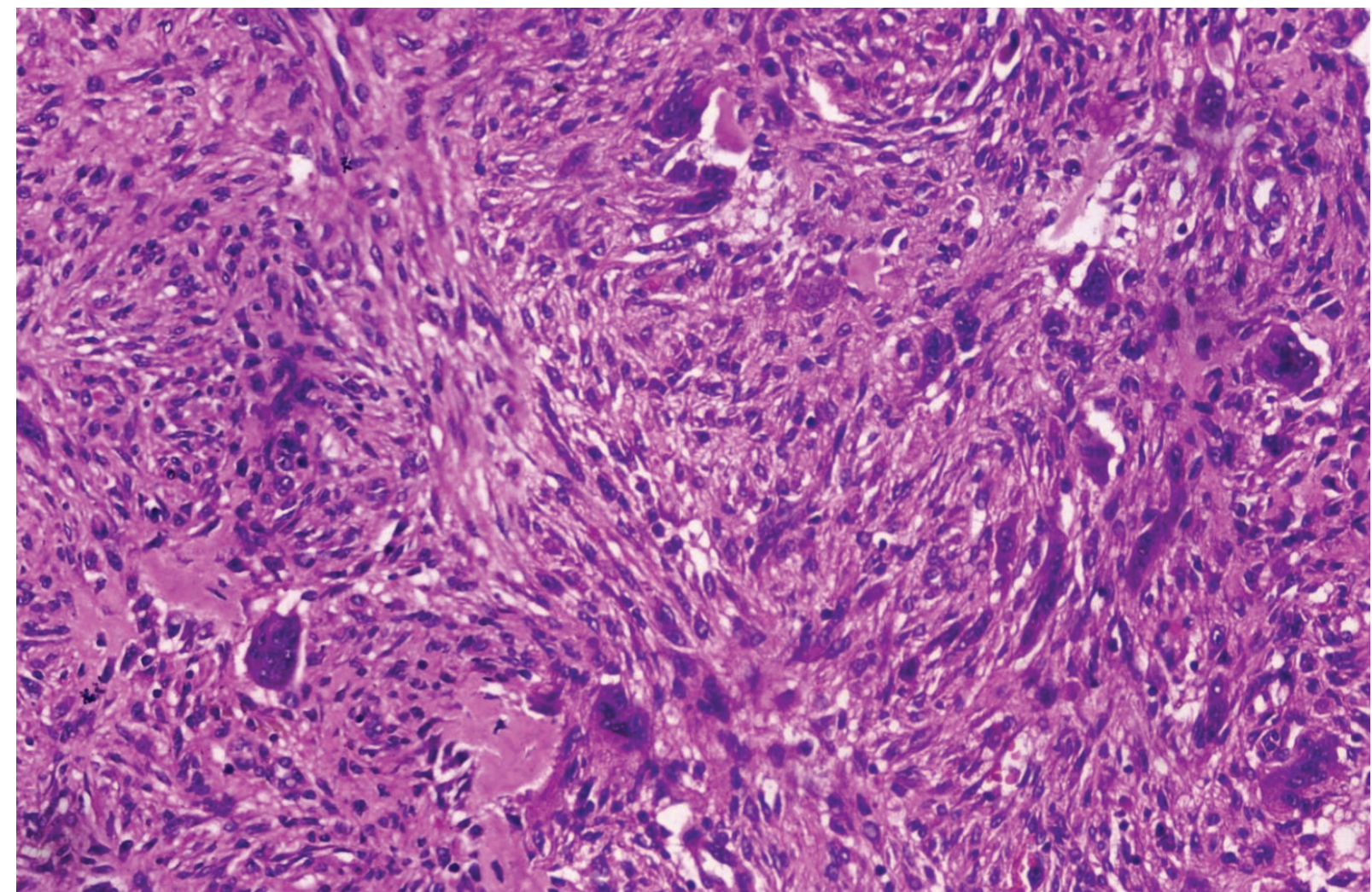
Impression: Evidence of hypodense lesion with peripheral rim like calcification measuring 5.2x3.6x3.2 cm noted in erector spinae on right side at D6-D7 vertebral level

Possibilities that were considered:

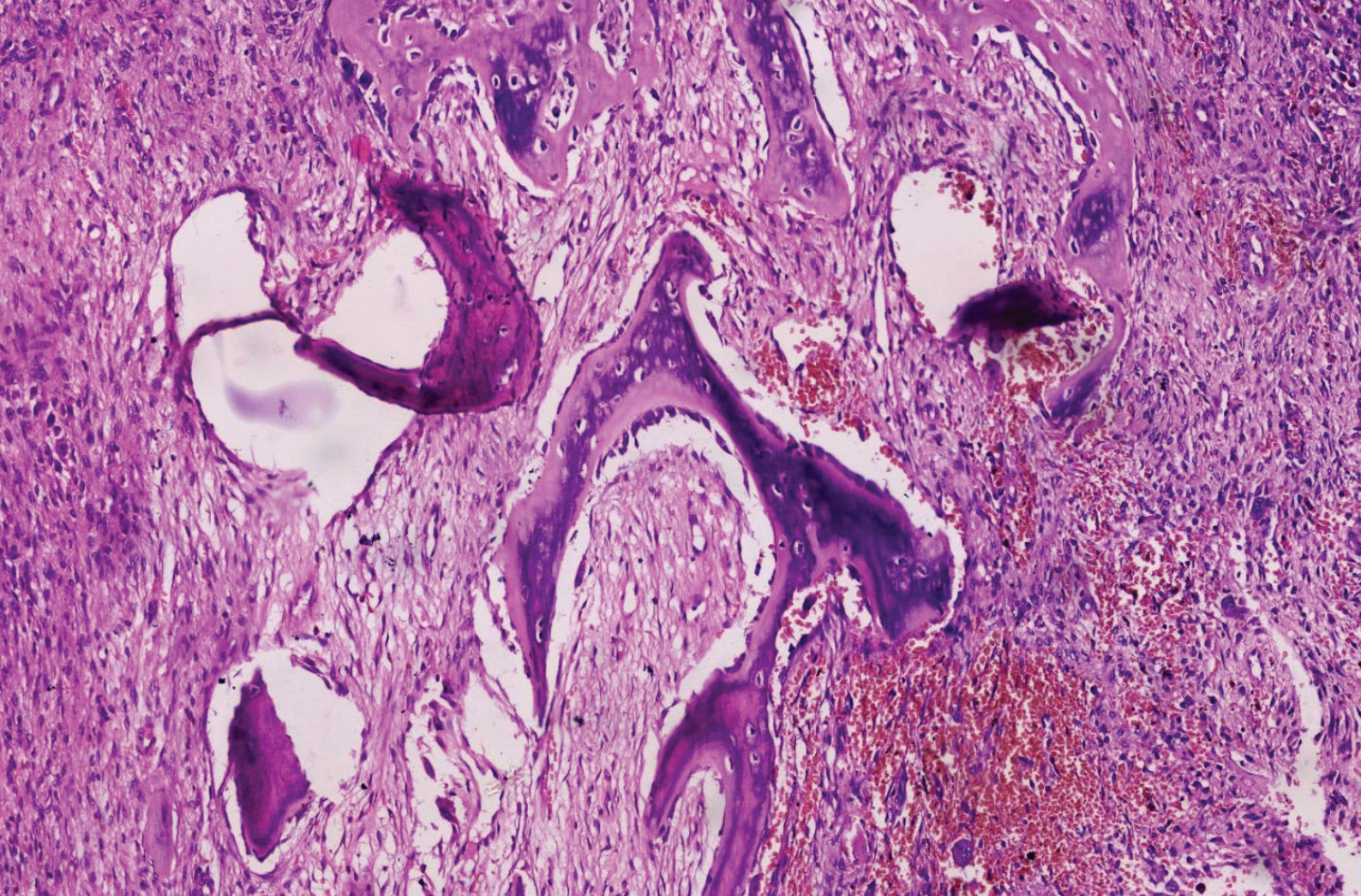
- Chronic hematoma
- Myositis ossificans
- Aneurysmal bone cyst
- Possibility of soft tissue sarcoma could not be completely excluded



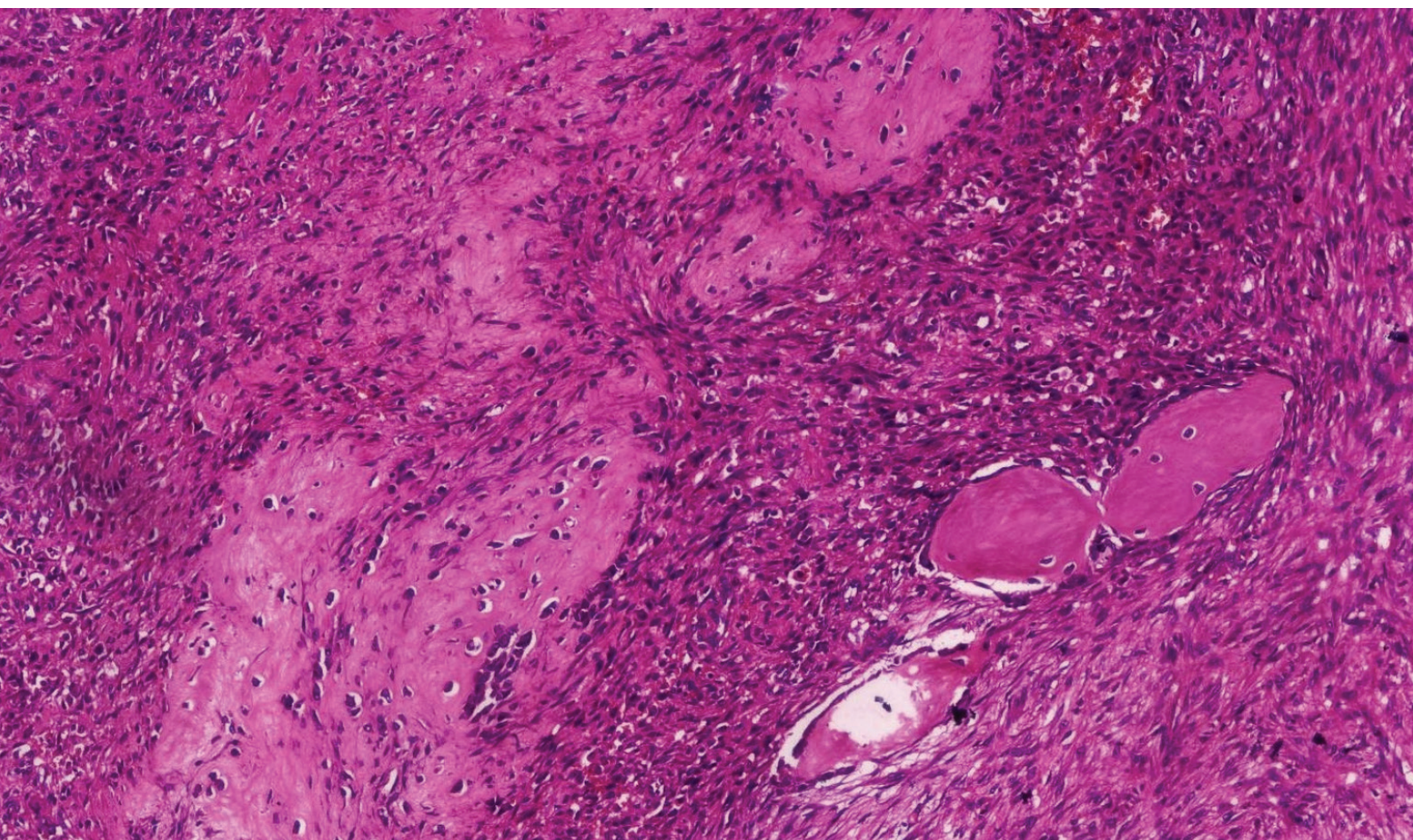
H&E-stained section under low power magnification showing tumor tissue with multiple blood-filled cystic spaces.



H&E-stained section under 40X magnification showing tumor composed of sheets of oval to spindle shaped cells with spindle shaped, vesicular nuclei and consisting of plenty of osteoclastic giant cells.



H&E stained section under low power magnification showing curvilinear bony spicules with ossification.



H&E stained section under low power magnification showing osteoid.

Case 2:

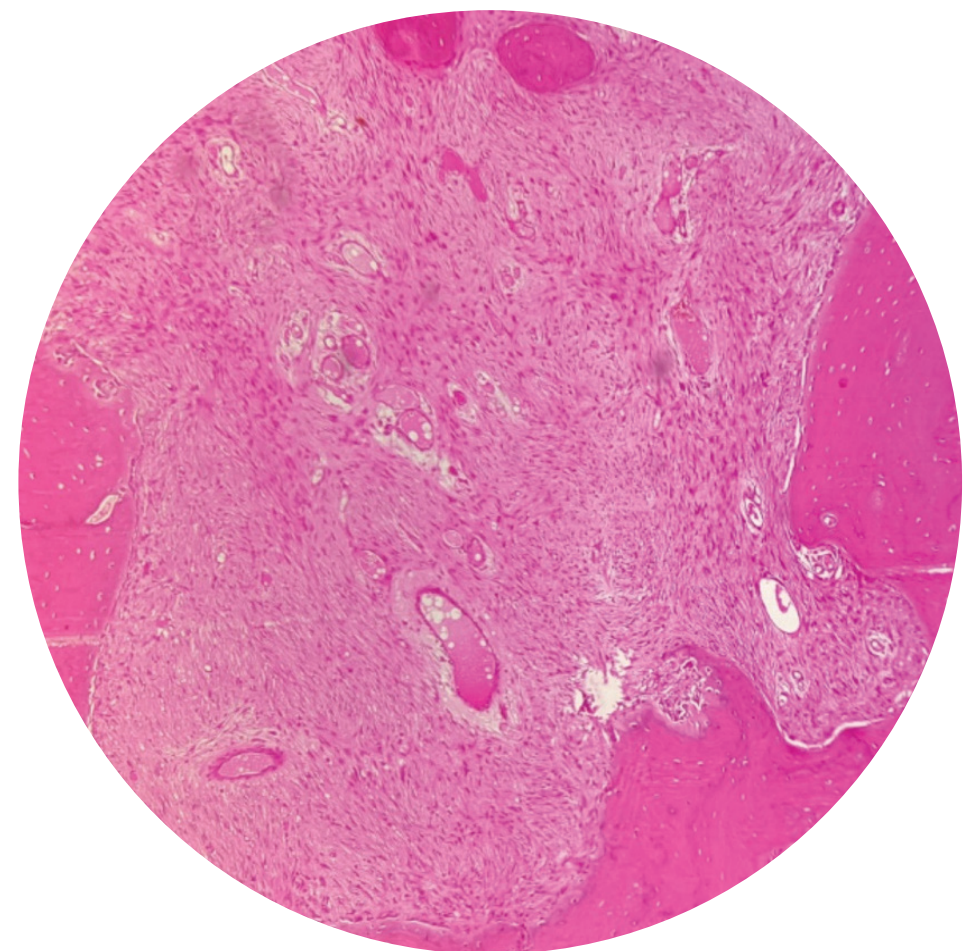
A 15 year old boy presented to the orthopedic surgeon with pathological fracture just below in the knee joint.

Swelling was insidious in onset, gradually progressed in size and pain increased since 2 months.

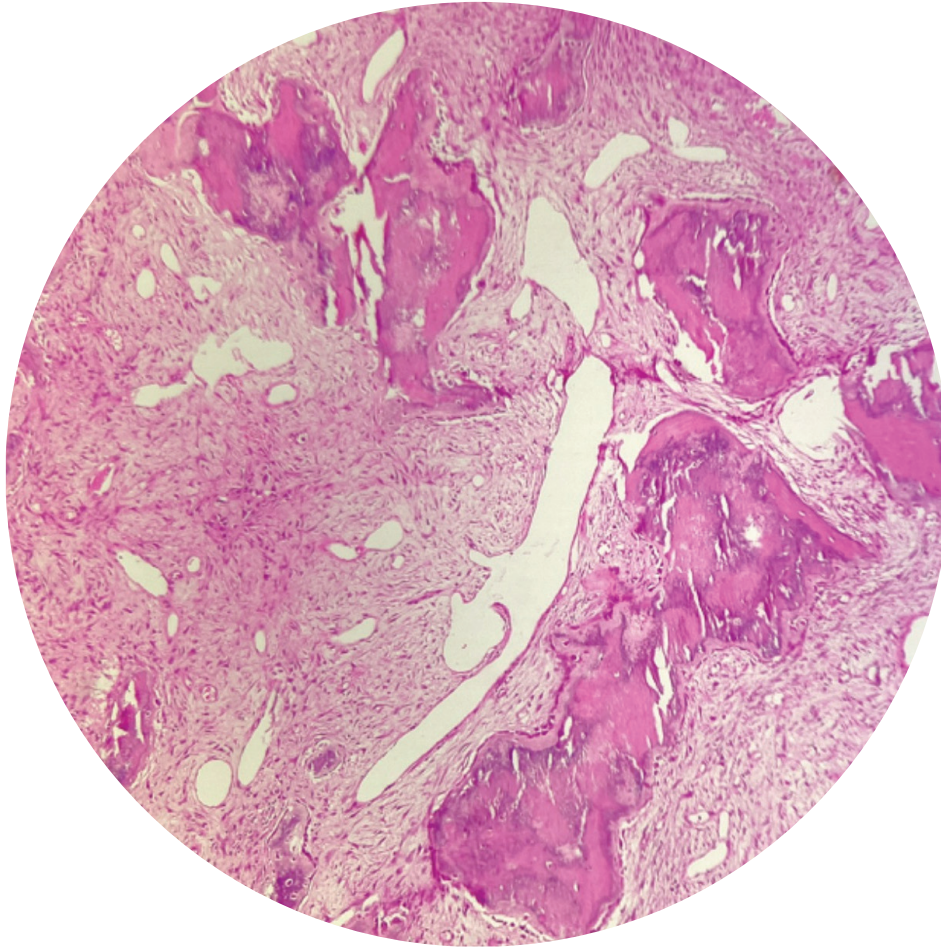
X ray revealed a metaphyseal lesion which has osteolytic in nature

Rest of the clinical examination was normal

Gross: Bony as well as soft tissue bits aggregating to 3 x 2 cm was received.



Above photomicrograph shows spindly cells amidst bony trabeculae. High power view showed occasional osteoclast type giant cell.



Above photomicrograph shows curvilinear bony spicules showing ossification & spindle cells arranged in a vague storiform pattern between the bony spicules. Delicate blood vessels are noted amidst the spindle cells.

Impression:

Non ossifying fibroma

- Synonymous with metaphyseal fibrous defect & fibro cortical defect
- A benign fibro-osseous lesion
- It occurs in age range from new born to 39 years
- It predominantly occurs in children and most cases are younger than 15 years
- Male and female are equally affected
- The tibia and fibula are affected almost exclusively, the lesions typically located in the anterior cortex.
- Metaphyseal lesion
- Approximately 20% of patients have ipsilateral involvement of the fibula. Rare examples have been described in the radius, ulna, and humerus.
- Microscopically irregular trabeculae of woven bone with osteoblastic rimming are seen surrounded by bland spindle cells in a collagenous background
- Isolated cytokeratin-positive cells are seen in approximately 75% to 95% of cases of Ossifying fibroma

Take Home Message :

Nonossifying fibroma (NOF) can be confused with fibrous dysplasia (FD). However the pathognomic feature of the latter is the presence of woven bone.

GNAS mutations are characteristic of FD, but not described in NOF.

Nonossifying fibroma may have secondary aneurysmal bone cyst like changes, especially in the periphery. Hence adequate sampling of the lesion is important.

In both these biopsies multiple blood filled spaces surrounded by fibrous tissue with osteoclast- like giant cells were seen in the periphery. If only the periphery were sampled the lesion could have been reported as aneurysmal bone cyst (ABC).

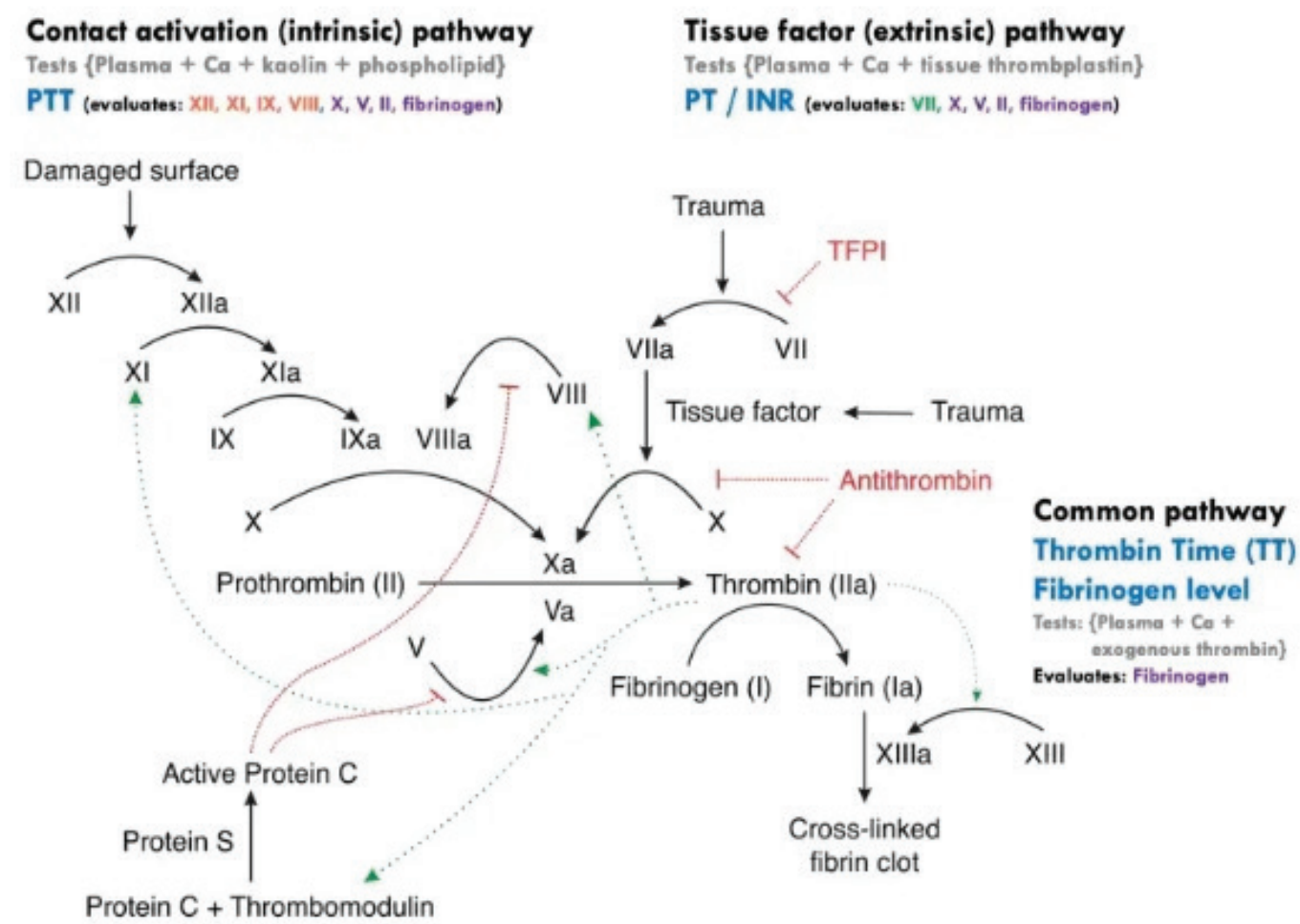
3. Diagnostic workup for hypercoagulable disorders

Dr. Shalini. R, Consultant Pathologist, Department of Hematology, and Clinical Pathology, Apollo Diagnostics GRL, Hyderabad.

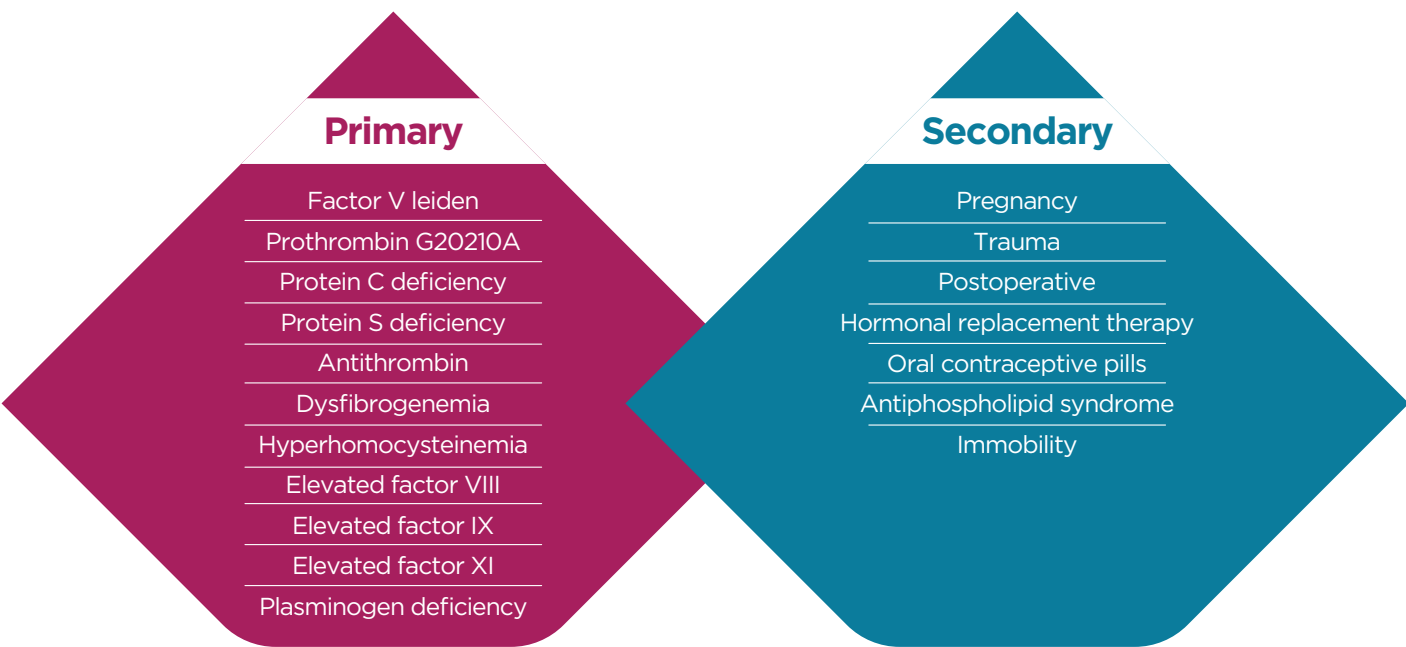
Foreword:

The coagulation and fibrinolytic systems are two separate but linked enzyme cascades that regulate the formation and breakdown of fibrin. The proteolytic cascades much alike, the complement system, are vital for maintenance of homeostasis. The ultimate goal of the pathway is to produce thrombin, which can then convert soluble fibrinogen into fibrin, which results in the formation of a clot. This article shall focus on the diagnostic approach to diseases with a pro-thrombotic state. The intricate mechanisms by which clotting is affected are beyond the scope of this article & are given as a diagram for the reader to revisit.

The Coagulation Pathway (1,2,3).



It is also worth our while to review the causes for hypercoagulable disorders & a comprehensive list of etiologies is given below:



Laboratory workup for hypercoagulable disorders:

Hypercoagulability studies should be ordered when one or more of the following criteria are met:

- 1) Few risk factors for arteriosclerosis
- 2) Recurrent thrombosis
- 3) A strong family history of venous thrombosis or
- 4) Young age onset of thrombosis (< 50 years).

Under these circumstances, one might consider obtaining tests for all the known hypercoagulable states.

Arterial thrombosis results from platelet-rich thrombi entering arterial circulation, whereas hypercoagulable states result in fibrin-rich thrombi producing mainly venous thromboembolism. Most arterial thromboses are secondary to underlying systemic disorders including dyslipidemia, hypertension, diabetes mellitus and atherosclerosis (4). A flow chart elucidating the same is given below.

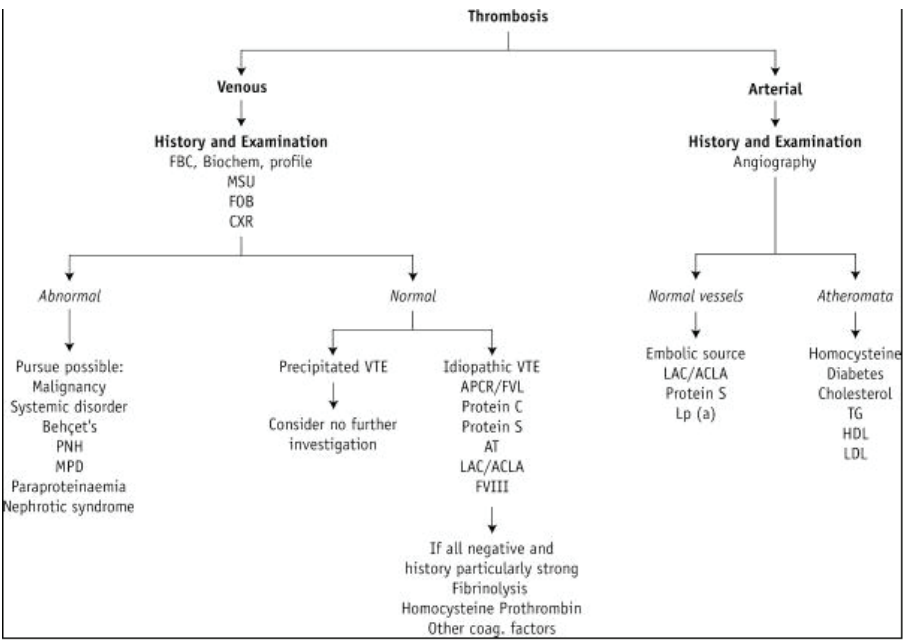


Figure 17.1 Investigations used for diagnosis of thrombosis. ACLA, Anticardiolipin antibody; APCR, activated protein C resistance; AT, antithrombin; CXR, chest X-ray; FBC, full blood count; FOB, fecal occult blood; FVL, factor V Leiden; HDL, high-density lipoprotein; LAC, lupus anticoagulant; LDL, low-density lipoprotein; Lp (a), lipoprotein (a); MPD, myeloproliferative disorder; MSU, midstream specimen of urine; PNH, paroxysmal nocturnal haemoglobinuria; TG, triglyceride; VTE, venous thromboembolism.

Testing for Antiphospholipid Antibodies (APLs):

Clinical features that suggest a workup for APLs are idiopathic thrombocytopenia, multiple miscarriages, thrombosis on the arterial and venous side, livedo reticularis, early age of thrombosis, noninfectious endocarditis, or a history consistent with lupus or collagen vascular disease. When testing for APLs, it is useful to wait 6 weeks after the stroke and when there is no evidence of active infection or inflammation, as falsely elevated and falsely depressed APL levels have been seen with acute thrombosis.

Testing for (Activated Protein C) APC resistance:

Testing for APC resistance from Factor V Leiden mutation or prothrombin gene mutation should be considered in patients with cerebral arterial or venous thrombosis without any precipitating factors, thrombosis during pregnancy, or a positive family history. The tests should be done 2 months after stroke, and the patient should have had heparin treatment stopped for at least a day, and warfarin stopped for at least 2 weeks prior, as thrombosis and anticoagulation affect these assays.

Testing for Protein S, Protein C, and Antithrombin III:

Features that should prompt testing for protein S, protein C, and antithrombin III deficiencies include venous or arterial thrombosis occurring in patients aged below 45 years, recurrent thrombosis without precipitating factors, thrombosis in unusual locations, a positive family history of thrombosis, thrombosis during pregnancy, warfarin-induced skin necrosis (protein S, protein C) or resistance to heparin (AT3 deficiency). These tests should also be performed 2 months after the stroke and after the patient has been taken off warfarin for at least 2 weeks. The tests should be repeated for confirmation, and family members should be tested (5).

Testing for Hyperhomocysteinemia:

Because hyperhomocysteinemia may respond to nutritional supplementation, it is reasonable to check for this congenital or acquired condition in all stroke patients. Although there is not yet strong evidence that treatment prevents

further recurrences, vitamin supplementation is quite safe and should be considered.

Testing for Sickle cell disease:

Hemoglobin electrophoresis should be performed in anemic patients at risk for sickle cell disease. Testing for the rare conditions of plasminogen and dysfibrinogenemia might be considered in patients when there is a high suspicion of a hypercoagulable state in the face of negative tests for the more common hypercoagulable disorders (5).

Important practical pitfalls in testing:

Preanalytical:

- The venipuncture should be ideally collected directly from a peripheral vein (antecubital vein). Extended tourniquet application might produce unnecessary venous stasis or in-vitro hemolysis
- The passage of blood through butterfly tubing and IV catheters might cause increased hemostatic alterations in comparison to blood collection using a conventional straight needle, directly into the tube.
- Sodium citrated tubes must be filled up to 90% of the nominal volume or to the mark noted on the tube if provided. The required ratio of sodium citrate to whole blood is 1:9. Under-filling of tubes is another important source of error and may affect laboratory results. An insufficient volume for testing greatly modifies the fixed blood to-anticoagulant ratio.
- Mixing samples is an important way to prevent in-vitro clot formation. Sometimes samples are inappropriately mixed or left unmixed for a long time, thereby avoiding full contact of the blood with the anticoagulant, which determines partial clotting.
- Vigorous shaking, vortexing or agitation of blood samples should be avoided in order to prevent inducing haemolysis or spurious platelet and factor activation that may result in shortened clotting times or false elevation of clotting factor activity in specimen tests

- Hemolysis can affect some tests of haemostasis, either because of the presence of thromboplastic substances or interference of haemoglobin pigment with photo-optical systems.
- Haemolysis may lead to statistically significant increases in PT and D-dimer. The aPTT can be falsely prolonged or shortened and AT and fibrinogen decreased by in vitro haemolysis
- Plasmas that are lipemic and icteric may also affect analytic results by interfering with optical absorbance or impeding light transmittance. Mechanical and/or electromechanical methods for clot detection should be utilized, when possible, for these plasma samples
- Double centrifugation significantly reduces the residual number of platelets in a sample and can be performed to produce PPP such that the post centrifugation plasma platelet count is less than or equal to 10x10⁹/L. Residual platelets in plasma have been known to affect phospholipid-dependent coagulation tests through the exposure from platelet membranes of anionic phospholipids that quench LA activity (6).
- Using relative centrifugal forces greater than 1500g is not recommended as this may induce platelet activation, haemolysis or other unwanted effects
- It is important to use an automatic pipette because it permits slow and linear suction, unlike plastic pipettes that pose a risk of getting a high rate of residual platelets.

Conditions for the interval from sampling to analysis:

For routine coagulation testing like the PT and the aPTT, storage of uncentrifuged samples at room temperature up to 6 hours may yield acceptable results. However, a shorter delay is desirable. Whole blood assays should be performed within 4 hours of blood sampling and centrifugation should ideally be done within 1 Hour.

Cold storage of citrated whole blood prior to centrifugation, by placing samples either in an ice bath or in refrigerated (2-8 °C) storage, is no longer recommended. Improper storage of whole blood at cold temperature may cause VWF and factor VIII values to fall below normal reference threshold levels, which may potentially lead to a false suspicion of hemophilia A or VWD due to inappropriate pre-analytical handling of blood.

PT, aPTT and factor VIII tests cannot be performed from frozen samples.

Analytical aspects:

- For analyses that can be performed on frozen plasma, freezing should be fast (using rapid freezing technique like liquid nitrogen), and samples should be preferably stored at -70 °C (or below) rather than -20 °C. Plasma samples frozen at minus 20 °C remain stable for 2 weeks for most coagulation parameters (6).
- The samples have to be thawed at least 5 min in a water bath at 37 °C and not at room temperature, on a bench or in a microwave oven. After thawing they should be gently stirred (6).
- **Repeated freezing & thawing of reagents used in testing is to be avoided.**
- Uncritical interpretation of laboratory results leads to misdiagnosis and thrombophilia testing exemplifies this. If erroneous and over diagnoses are to be avoided, the following points must be recognized:
- Normal ranges for antithrombin and proteins C and S are wide and patients with deficiency may have levels that are only slightly below normal. Repeat testing is often required for diagnostic confidence. For example, laboratory quality assurance data have shown that for protein S in particular the rate of laboratory error in diagnosis can be as high as 20%.
- Pregnancy induces a state of resistance to the anticoagulant effect of activated protein C, which mimics the presence of factor V Leiden.
- Pregnancy and OCP use lead to a fall in plasma protein S concentration.

- Antithrombin concentration is reduced in acute thrombosis, by heparin treatment and in pre-eclampsia.
- Proteins C and S are vitamin K dependent and their concentrations are reduced by warfarin treatment (7).

Afterword:

Investigation of diseases involving the various prothrombotic & antithrombotic proteins in the body, integral to hemostasis is tricky & requires ample expertise. Even with the best of scrutiny errors may creep in & standardization can fail. A robust understanding of the physiology of coagulation, clinical correlation, practical knowledge of the pitfalls which may result in deviant results & stringent adherence

to testing guidelines recommended by statutory bodies is vital to ensure patient safety.

REFERENCES

1. Khan S, Dickerman JD. Hereditary thrombophilia. Thrombosis journal. 2006 Dec; 4(1):1-7.
2. Heijboer H, Brandjes DP, Buller HR, Sturk A, ten Cate JW: Deficiencies of coagulation-inhibiting and fibrinolytic proteins in outpatients with deep-vein thrombosis. N Engl J Med 323(22):1512-6. 1990 Nov 29
3. Esmon CT, Protein C: The regulation of natural anticoagulant pathways. Science 1987, 235: 1348.
4. Ashraf N, Visweshwar N, Jaglal M, Sokol L, Laber D. Evolving paradigm in thrombophilia screening. Blood Coagulation & Fibrinolysis. 2019 Jul; 30(5):249.
5. Moster ML. Coagulopathies and arterial stroke. Journal of Neuro-Ophthalmology. 2003 Mar 1; 23(1):63-71.
6. Magnette A, Chatelain M, Chatelain B, Ten Cate H, Mullier F. Pre-analytical issues in the haemostasis laboratory: guidance for the clinical laboratories. Thrombosis journal. 2016 Dec; 14:1-4.
7. Merriman L, Greaves M. Testing for thrombophilia: an evidence-based approach. Postgraduate medical journal. 2006 Nov 1; 82(973):699-704.

4. Viral carcinogenesis – A spell that awakens an old genie from the new bottle.

Dr. Marquess Raj – ZTC – Tamil Nadu & Pondicherry

Foreword:

Jared Diamond in his Pulitzer Prize winning work ‘Guns, germs & steel’ gives a convincing account of how germs brought about significant changes in our history. From exterminating entire populations to ushering in the need for scientific progress, germs share a poignant bond with mankind. Among the germs, viruses are fascinating. Miniscule organisms that possess a rather minimalistic shell enclosing sophisticated armament that can wreak disease ranging from common cold to life threatening cancer or even wipe out millions of humans from the face of earth.

Back to brass tacks:

Cutting edge technology has unravelled many a mystery underpinning viruses as the causative agents in diseases such as Paget’s disease & even rare carcinosarcomas (1). Traditional medical teaching deems ‘syphilis’ as ‘the great impostor’ & the spirochete can produce a gamut of lesions in humans. The sheer range of lesions the human papilloma virus (HPV) can make manifest in the living is impressive to say the least & does not lag behind T.pallidum. The complexity of lesions ranges from the common wart to the awe evoking ‘tree man syndrome’ in which the afflicted individuals’ extremities are transformed much akin to the appendage of a tree (2). Noteworthy is that this archaic foe studied by Papanicolaou is one of the hardest viruses known to humans & is not even killed by conventional sanitizers or even glutaraldehyde. While some of the skin lesions that HPV causes may just be of cosmetic annoyance, the larger brunt inflicted by the virus is by the way of cervical cancer (3).

The COVID pandemic has not yet been declared as ‘over’ by the WHO & yet we have news of

new variants as well as mutant virus cousins causing significant impact on health (4). Age old practices such as ‘masking’ & ‘sanitation’ took center stage exposing the vulnerability of humans to an age-old foe in an era where health advancements such as heart transplants have become commonplace.

Cancer causing viruses are not new to humans. But in the recent years many more cancers have been narrowed down to viral etiology & viruses indeed act as ‘inducers’ as well as ‘promoters’ in cancer pathogenesis. Viruses such as the Rous sarcoma virus can produce sarcomas in chicken at enormously fast rate when a cell free extract of nuclear material is injected in experimental conditions (5). Hypothetically, the whole human race could face calamity of sci-fi proportions if faced with a sinister sarcoma causing virus which after acquiring a handful of mutations, decides to spread by a COVID like fashion.

Parting remarks:

Viral carcinogenesis itself is evidence that cancer cannot be secluded to the confines of non-communicable disease & HPV is a great example of the same. HIV took the world by storm when it was discovered nearly 4 decades ago. But we have learnt valuable lessons with time & science has progressed to an extent that HIV is not a death sentence anymore. The COVID pandemic has taught us those communicable diseases can never be written off & we will have to contend with many more such genies which may be held up in new bottles, washed ashore in some random beach, held back by spells of dormancy.

Footnotes:

1. Paramyxoviruses are implicated in Paget’s disease. A bone disorder with a pathogenesis fondly phrased as a ‘collage of matrix madness.’

2. The maculopapular rash of syphilis can mimic pityriasis rosea. Epidermodysplasia verruciformis, caused by HPV 5 & 8 can either take an innocuous form or result in coalescing skin lesions that can simulate tree bark!

3. Certain HPV subtypes such as 1 & 2 cause warts which can be treated easily. Whereas the subtypes that cause cervical cancer are infamously called ‘high risk’ subtypes & account for being the fourth most common cause of cancer related death globally.
4. The Rous sarcoma virus was the first virus in which oncogenesis was demonstrated experimentally. Epstein Barr virus (EBV) is implicated in a multitude of neoplasms.

5. As of 10th March 2023 the COVID pandemic caused 6.88 million confirmed deaths causing it one of the deadliest in history.
- Fun fact:** The great impostor, a phrase often used to describe the lesions produced by Syphilis, reminds one of the movies ‘The great dictator’ which was Charlie Chaplin’s first movie with dialogue in it. Chaplin was reluctant to adopt ‘sound’ initially as he wasn’t entirely convinced that movies with dialogue could convey comedy better than silent ones. But the great dictator was made & the rest you know is history.

5. Quiz – Sleuthing with a semen sample

Dr. Marquess Raj - Co-editor AD express

The only alternative to assessing a man’s fertility other than asking him to sire a child is by examining his semen. There plenty of subtle nuances to semen analysis & being informed about the interpretation of abnormal findings is vital.

In ‘The study in scarlet’ the much-celebrated detective Sherlock Holmes tosses a few crystals into a beaker containing microscopic amounts

of blood & demonstrates the ‘benzidine reaction’ with aplomb. Similarly, the seminal fluid contains a multitude of secretions from the male accessory sex organs. Pathology of these organs can be narrowed down by testing the presence or absence of specific markers. Knowledge of these markers & the corresponding organ is vital, elementary though it may seem!

Match the following markers of the male accessory sex organs with site of secretion (Same option can be used multiple times)

- | | |
|---------------------------|--------------------|
| 1. Fructose | A. Prostate |
| 2. Total Zinc | B. Seminal vesicle |
| 3. Total acid phosphatase | C. Epididymis |
| 4. Alpha glucosidase | D. Testis |
| 5. Carnitine | E. Cowper glands |

Answers to the pervious quiz in the July 23 issue:

The appropriate ‘riddles’ are matched with their respective epithelium

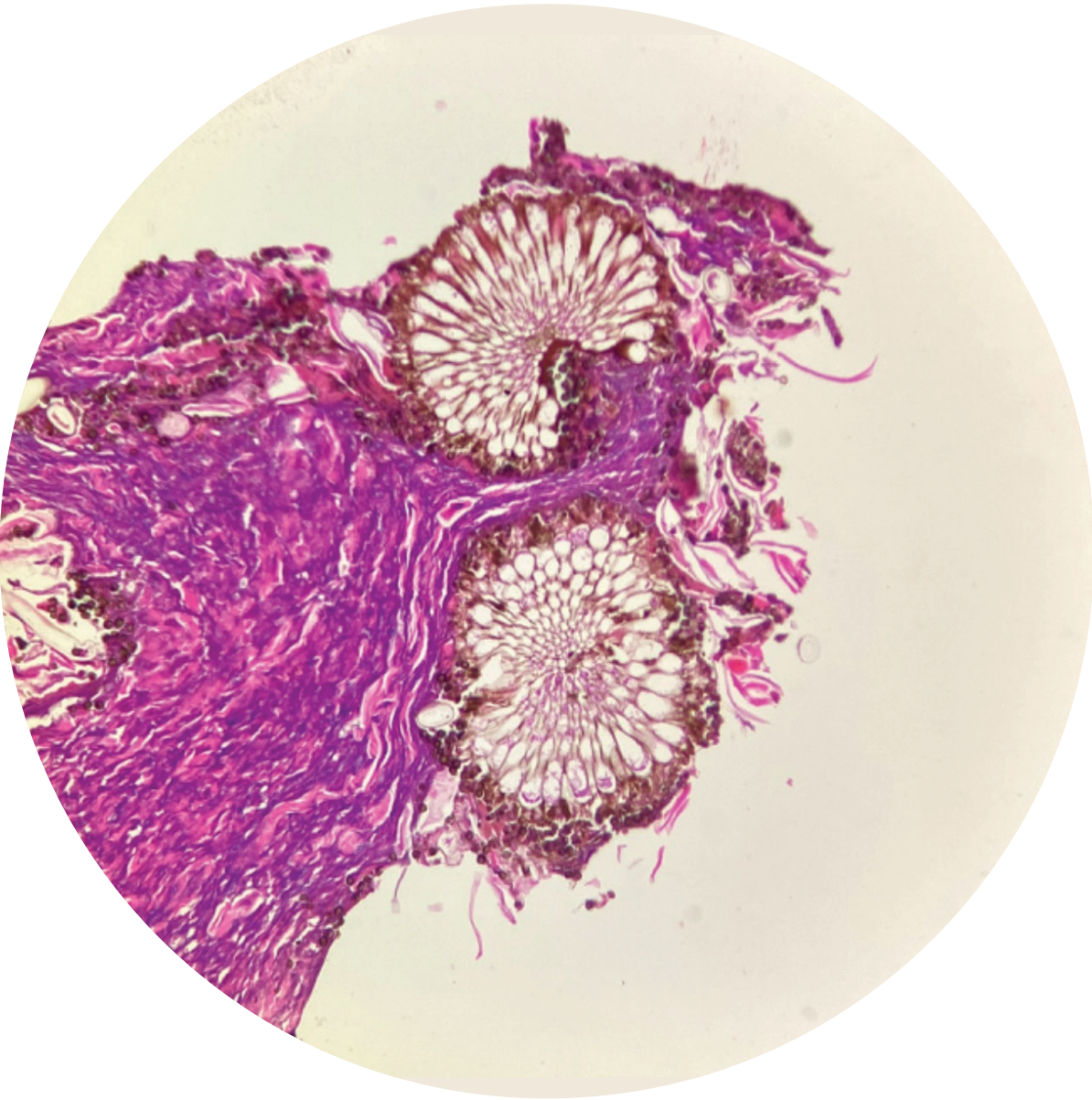
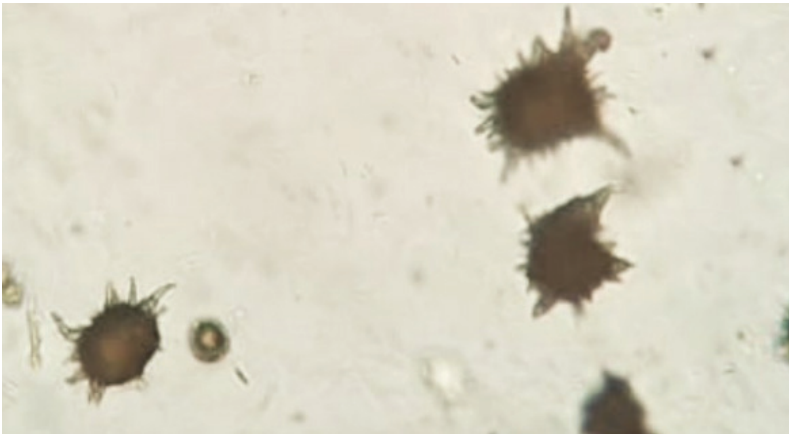
The following riddles are matched to the correct epithelium

- | | |
|---------------------------------------|---------------------|
| 1. Pavement like, flat as pancakes | A. Squamous |
| 2. Tall in stature possess fine hairs | B. Columnar |
| 3. Top layer cells are rounded | C. Transitional |
| 4. Like a stack of boxes | D. Cuboidal |
| 5. Nuclei not in a regular row | E. Pseudostratified |

6. Quiz - Know your moulds: An example from the ear

Dr. Mir Salman Ali – Head of Microbiology, Global reference laboratory, Hyderabad

A. Identify the fungus shown below amidst fibro collagenous tissue, from an ear biopsy sample. A brief of the same shall be given in the next issue.



B. Answer to identify the crystal in the previous issue: Ammonium biurate crystals

Clinical Significance:

Ammonium biurate crystals generally appear as brown or yellow-brown spherical bodies with irregular spikes (“thorn-apples”). In some urine samples, they do not have irregular protrusions but have smooth borders and can resemble calcium carbonate.

Though possible in urine of any pH, their formation is favoured in neutral to acidic urine. They are frequently seen with amorphous urates. These crystals are noted in conditions wherein there is high protein breakdown such as chemotherapy.

Fun fact: They can be seen in urine from normal Dalmatians & English Bulldogs

CME and Conferences Conducted



Bihar



Coochbehar



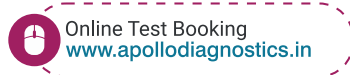
Tirupati



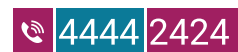Yamuna Nagar



www.apollodiagnostics.in



CUSTOMER CARE



Follow us on

