Apollo DIAGNOSTICS®

Expertise. Empowering you.

AD Express

Oct 2023

On The Right Track, For Precise Results

Editorial Board

From the Editors' Desk

Dear Reader,

With Octoberthe season of festivity sets in. May the season of joy & festivity usher in positivity & hope in our lives & work. We wish our readers a happy festive season & take opportunity to thank all our patrons for the immense support we have garnered over the years.

We will continue to encourage contributors to write on their experiences & share their expertise.

In this edition, histopathology takes center stage& lesions ranging from infectious diseases to benigntumors as well as esoteric circumstances are covered in this issue. The opinion of individual practitioners also matters as much as anybody in lab medicine. Astute judgment & robust background of the branch enables lab medicine specialist to hone a set of skills that only get better with time. In a first-timeendeavor, we share the expertise of the lab medicine specialists from case series studies as well as experience from practice titled; 'Expert opinion'.

In our case report section, we share an excellent example of interdisciplinary cohesion in managing a patient with parathyroid adenoma. Apollo diagnostics is committed to the adoption of best practices in lab medicine& this case report is an epitome of the same. Our next case report delves into rectal tuberculosis which can mimic malignancy. We have introduced another dimension to our quizzes by introducing 'What's on the stage', which reinforces the fact that a strong background of cell morphology will augur good for any laboratory. We expect our creative tendencies to gravitate towards biochemistry ballads, serology sonnets & musings from microbiology in the forthcoming issues.

We thank Gautam Roy & Hemaal Dhar for formatting copy after copy & giving AD express shape.AD express has gained considerable impetus by the way of your contributions & we welcome more from you all. Also humbly request you to share your feedback on 'AD express&we assure you that feedback from you will give us scope to improve.

Wishing you all a Happy Dussehra, a happy festive season &a great year ahead!

Best regards,

Dr. Marquess Raj M.D. Dip. N.B (Path), MBA (HM)
ZTC – TN & Pondicherry
marquess.raj@apollodiagnostics.in

Dr. Shalini Singh M.D (Path), IFCAP, DMSC (Endocrine)
Lab Director, Global reference lab, Hyderabad
shalini.singh@apolloclinic.com

Contents

CASE REPORTS

1. Interdisciplinary cohesion in managing a case of parathyroid adenoma – A case report

Dr. Marquess Raj Swamynathan, Dr. Dhandapani Subramani Kumaresan, Dr. Chidambharam Choccalingam, Dr. Srivatsan Ravi & Dr. Sivaramakrishnan Ramachandiran

Introduction:

Interdisciplinary cohesion is indispensable for patient management. Exchange of scientific information between the various specialties of medicine paves the way forward to productive patient outcomes. We share an example of interdisciplinary cohesion in the management of a patient with parathyroid adenoma.

Parathyroid adenoma is a benign neoplasm derived from parathyroid parenchymal cells. The parathyroid glands play a key role in calcium homeostasis. Parathyroid adenomas are responsible for hyperparathyroidism in 30 to 90 % of the cases [1]. Hyperparathyroidism can present with a multitude of symptoms. Some as innocuous as generalized weakness & some which may involve pain such as renal stones. Even psychiatric manifestations have been described in hyperparathyroidism.

Hence a patient with hyperparathyroidism could seek the help of the various specialists in medicine ranging from endocrinologists to urologists. Cohesion, exchange of ideas & a patient centric approach is essential in management of such cases. The old adage 'too many cooks spoil the broth' is a reminder that conflict & exertion of superiority of one branch to another will not augur good for the patient. Our case report is an illustration of how teamwork and an interdisciplinary approach between different branches of medicine will stand the patient in good stead [2].

Case presentation:

A 74-year-old man presented to the surgeon with nephrolithiasis, weakness & fatigue. An endocrinologist's opinion was sought. It came to light through radionuclide scan & parathormone (PTH) testing that the patient harbored a parathyroid adenoma. A diagnosis of primary hyperparathyroidism was established.

The surgeon had planned for left lower parathyroidectomy in his hospital & testing for intraoperative PTH levels. A drop in the IOPTH > 50 % is considered as successful excision of the parathyroid glands [3,4,5]. However, the hospital laboratory did not have the facility to test of intraoperative PTH levels. The clinical team came in touch with the laboratory team of Apollo diagnostics. The reference laboratory of Apollo diagnostics was situated 20 km away from the location where the surgery was to take place.

However, with meticulous planning & exchange of ideas, it was decided that the surgery be performed in the early hours of a Sunday morning. The early hours of Sunday were chosen to avoid the brunt of the city's traffic. The base line as well as IOPTH samples were transported to the testing facility by ambulance within an hours' time & the samples were tested after all the pre-requisites for sample testing such as QC checks were passed. The results were satisfactory as the drop in PTH level was > 50 %

The excised glands were subjected to histopathological study & the diagnosis of parathyroid adenoma was confirmed.

Discussion

Parathyroid adenomas are the commonest cause of primary hyperparathyroidism & account for 85 to 95 % of the cases [1,6]. Patients with parathyroid adenoma can present with bone disease, nephrolithiasis, gastrointestinal disturbances, central nervous system alterations & cardiac manifestations.

Grossly, parathyroid adenomas tend to be located in the lower glands > upper glands & the same held true in our patient. However, despite many attempts the best imaging technique for localizing abnormal parathyroid tissue, the best "technique" for successful localization of abnormal parathyroid glands is an experienced surgeon.

The patient on whom left lower parathyoidectomy was done presented with nephrolithiasis, weakness & fatigue. The radionuclide scan as well as PTH levels of the patient suggested primary hyperparathyroidism & the cause was ascribed to parathyroid adenoma. It is worth recalling that parathyroid adenomas are associated with MEN (multiple endocrine neoplasia) syndromes.

Intraoperative estimation of PTH is termed "biochemical frozen section. The expertise of the biochemist cannot be understated & thorough scrutiny of pre-requisites such as quality control (QC), analyzer maintenance & sample acceptability criteria were given due attention prior to the testing of the samples.

On the basis of the Irvin criterion, an intraoperative PTH drop >50% from the highest either pre incision or pre-excision level after parathyroid excision was considered a surgical success. Both baseline & intraoperative PTH samples were collected from the patient & were transported to the testing facility within 1 hour. The percentage difference between pre-operative & intraoperative PTH levels was 165 %, which satisfied Irvin criterion [1,5,6].

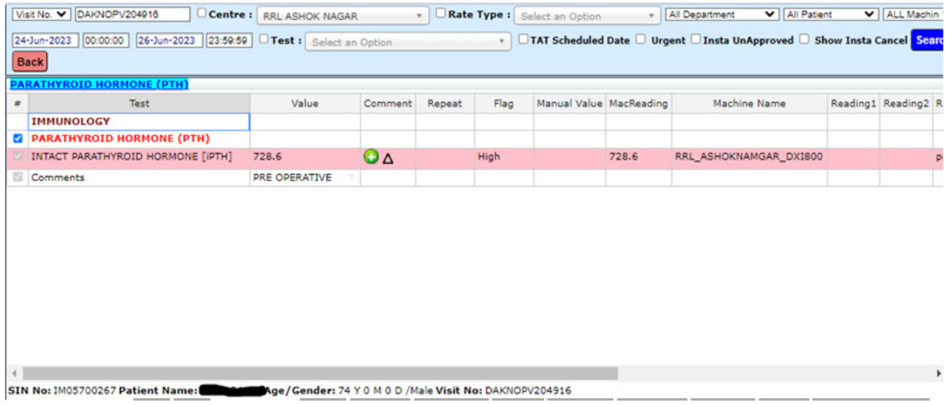

Visit No. DAKNOPV204916 | Centre : RRL ASHOK NAGAR | Rate Type : Select an Option | All Department | All Patient | ALL Machin
24-Jun-2023 00:00:00 26-Jun-2023 23:59:59 | Test : Select an Option | TAT Scheduled Date | Urgent | Insta UnApproved | Show Insta Cancel | Sear
Back

PARATHYROID HORMONE (PTH)

#	Test	Value	Comment	Repeat	Flag	Manual Value	MacReading	Machine Name	Reading1	Reading2	R
	IMMUNOLOGY										
	PARATHYROID HORMONE (PTH)										
	INTACT PARATHYROID HORMONE [IPTH]	728.6			High		728.6	RRL_ASHOKNAMGAR_DXI800			p
	Comments	PRE OPERATIVE									

SIN No: IM05700267 Patient Name: [redacted] Age/Gender: 74 Y 0 M 0 D /Male Visit No: DAKNOPV204916

Picture 1: Pre-operative PTH levels as shown in the laboratory LIS

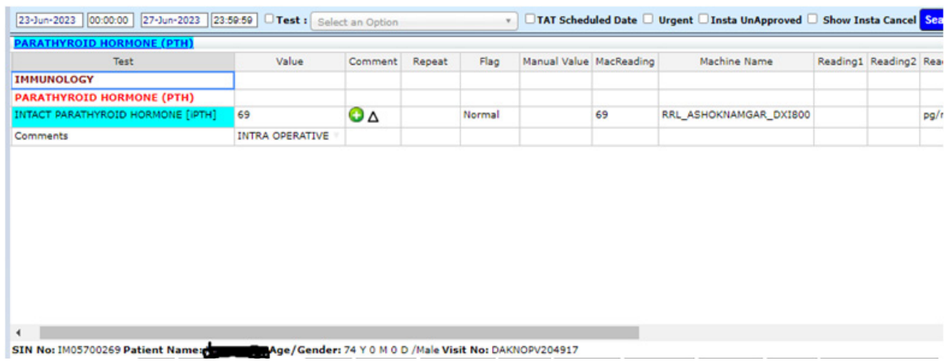

23-Jun-2023 00:00:00 27-Jun-2023 23:59:59 | Test : Select an Option | TAT Scheduled Date | Urgent | Insta UnApproved | Show Insta Cancel | Sea

PARATHYROID HORMONE (PTH)

Test	Value	Comment	Repeat	Flag	Manual Value	MacReading	Machine Name	Reading1	Reading2	Rea
IMMUNOLOGY										
PARATHYROID HORMONE (PTH)										
INTACT PARATHYROID HORMONE [IPTH]	69			Normal		69	RRL_ASHOKNAMGAR_DXI800			pg/r
Comments	INTRA OPERATIVE									

SIN No: IM05700269 Patient Name: [redacted] Age/Gender: 74 Y 0 M 0 D /Male Visit No: DAKNOPV204917

Picture 2: Intra-operative PTH levels as shown in the laboratory LIS

Histopathological examination:

The left lower parathyroid gland received in the laboratory was weighed before cutting. The weight of the parathyroid gland was 3 grams. As given in literature the weight of the parathyroid rarely exceeds 1 gram if the underlying pathology is hyperplasia [9].

As stromal fat is completely absent in parathyroid adenomas. Demonstration of the same by means of tissue frozen section is described in literature as a means of differentiating adenoma from hyperplasia. However, the risk incurred by not performing a frozen section was evaluated in this case. The surgeon & the laboratory team concluded that documentation of IOPTH levels & routine histopathological examination would suffice in confirming a diagnosis of parathyroid adenoma [6,7,8].

The parathyroid glands received in the laboratory after surgery had a discrete nodular appearance suggesting adenoma. On cutting, the surface of the parathyroid was homogenous gray white with areas of congestion. The gland was subjected to histopathological examination.

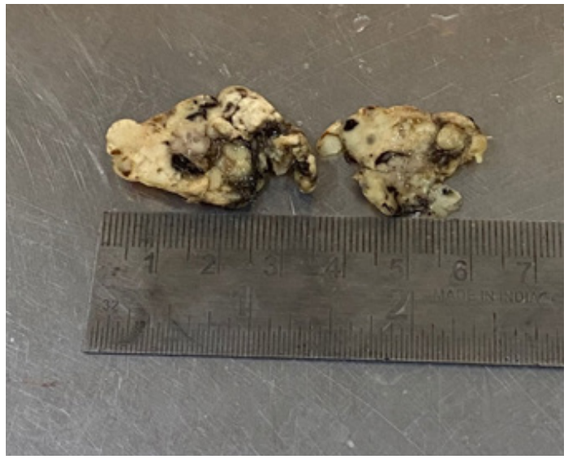

Gross image of the left lower parathyroid shows homogenous gray white surface & specks of congestion.

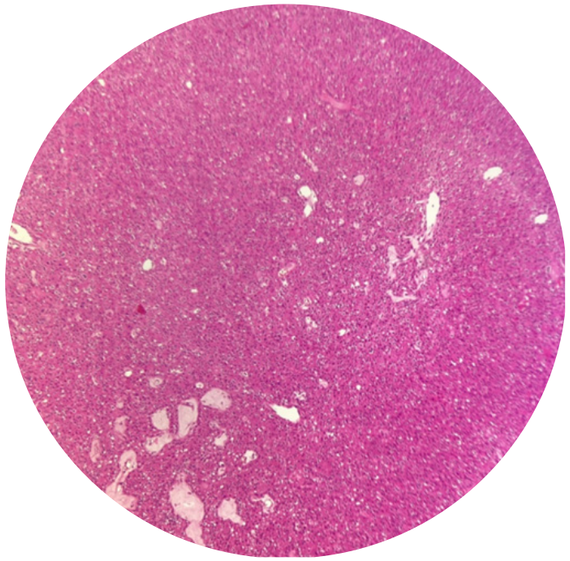

Photomicrograph (4X). Microscopic examination done on sections taken from the parathyroid revealed sheets of eosinophilic cells in an acinar pattern with interspersed delicate vessels on low power.

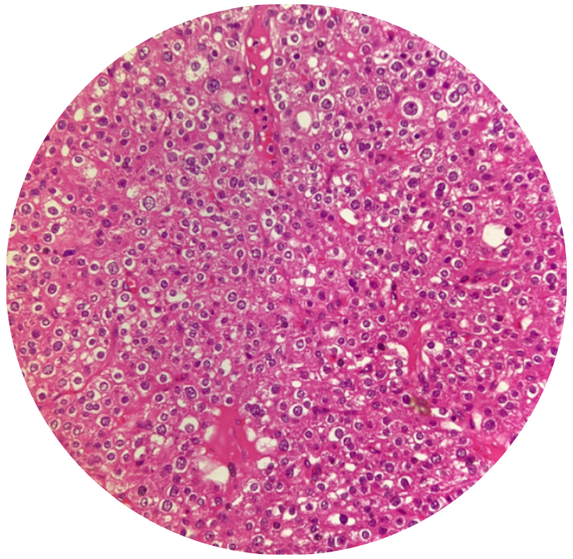

Photomicrograph (40X).Sections studied from the parathyroid showed sheets of polygonal cells with abundant cytoplasm, vesicular nuclei & 'salt & pepper' chromatin.

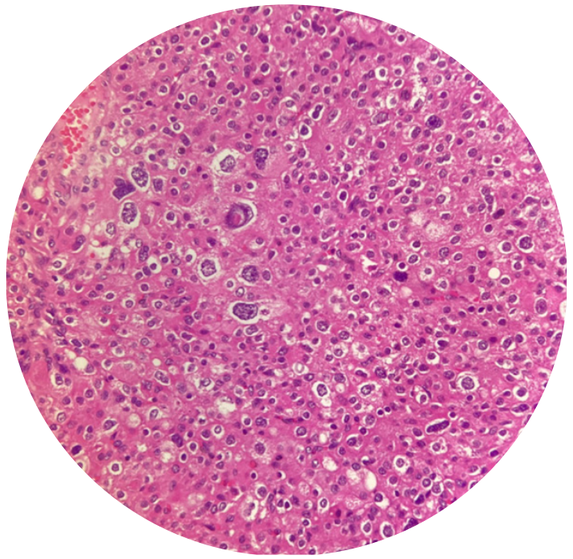

Photomicrograph (40 X). On higher power few areas showed cells with bizarre nuclei & binucleate cells. However, no necrosis or mitoses were noted.

Parathyroid adenomas, grossly are well circumscribed tumors or encapsulated tumorsoval measuring 1 to 3 cm. Chief cells are the predominant cells in parathyroid adenomas, however other cell types can be present in varying mixtures. The presence of clusters of cells with bizarre nuclei is fairly common & does not indicate malignancy. Stromal fat is more often than not absent in parathyroid adenomas & is considered a diagnostic feature. Likewise, lymphocytic infiltration of the intervening stroma & occasional mitoses are common features in otherwise benign parathyroid adenomas [9].

A diffuse growth pattern is the most frequent type of architecture encountered, but follicular, nesting, or pseudo papillary patterns may be encountered. Though immunohistochemistry has been described as an ancillary tool to study parathyroid neoplasms further, it is seldom required. In our patient, the gross & microscopic findings did show characteristic features of parathyroid adenoma & the same correlated with the clinical as well as biochemical findings [10].

Conclusion:

The biochemical findings & histopathology findings confirmed a diagnosis of parathyroid adenoma in patient who presented with symptoms of primary hyperparathyroidism.

Interdisciplinary participation in patient management is vital towards positive patient outcomes. Rapport & discussion between the various disciplines in medicine as well as the culture of 'putting the patient first' resulted in a positive outcome & successful management of the patient.

Exchange of information between the clinician & the pathologist & studied on exploring new reagents that will help pathologists discern cell morphology better will help towards positive patient outcomes.

2. Tuberculosis of the rectum, a mimicker of malignancy

Dr. Veena Singh, Consultant Pathologist, RHCC,Ambattur, Chennai

Abstract:

Gastrointestinal tract tuberculosis is uncommon. Anorectal tuberculosis is rare and can mimic malignancy. We present a case of 55-year-old female patient who came to the hospital with complaints of severe epigastric pain for one week with a history of vomiting, loss of weight and loss of appetite. Colonoscopy revealed a growth in rectum and the specimen was sent for histopathological examination to rule out rectal malignancy, which turned out to be rectal tuberculosis. The patient was treated successfully by anti-tuberculosis medications. Rectal tuberculosis should be included in the differential diagnosis of rectal masses. As these lesions occur so sparsely, they are often not suspected.

Introduction:

Extra pulmonary Tuberculosis remains an important part of the total tuberculosis cases all over the world[1]. Tuberculosis of the gastrointestinal tract occurs as a primary lesion or secondary to a focus of tuberculosis somewhere else in the body, most commonly in the lungs[2].

Case report:

A 55-year-old female was admitted in our hospital with complaints of severe epigastric pain for one week and history of vomiting, loss of weight and loss of appetite. There was no significant past medical history. Physical examination revealed mild pallor. She had no lymphadenopathy or hepatomegaly. Except this, the general and systemic examination was non-contributory.

Investigations revealed hemoglobin 9.0g/dL, total leucocyte count 6900/ cu mm (neutrophil 68%, lymphocyte 21%, eosinophil 4%, monocytes 7%), ESR 62 mm / hr. The patient had fasting blood sugar 107 mg/dL, urea17 mg/dL, and creatinine 0.8 mg/dL. Liver function tests showed normal bilirubin and enzymes. Urine examination revealed 3-4 epithelial cells and 2- 3pus cells. Ultrasonography of the whole abdomen did not reveal any abnormality. Chest radiograph was within normal limits. Endoscopy was performed which revealed antral erosion. Patient developed loose stools and vomiting. Feces for occult blood was found out to be positive. Colonoscopy was performed which showed a growth in the rectum. Biopsy was taken and the specimen was sent for histopathological examination to rule out malignancy but as the specimen was not adequate so a repeat biopsy was asked. Repeat rectal biopsy suggested tuberculosis rectum. AFB stain was done to confirm the diagnosis which also came out positive.(Fig 1-4). The patient was started on anti - tuberculosis therapy to which she responded very well.

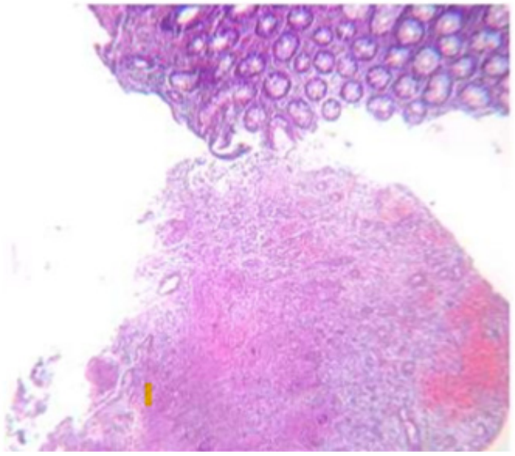

Fig-1: Scanner view showing a fragment of colonic mucosa with ulceration and fragment of necrosis

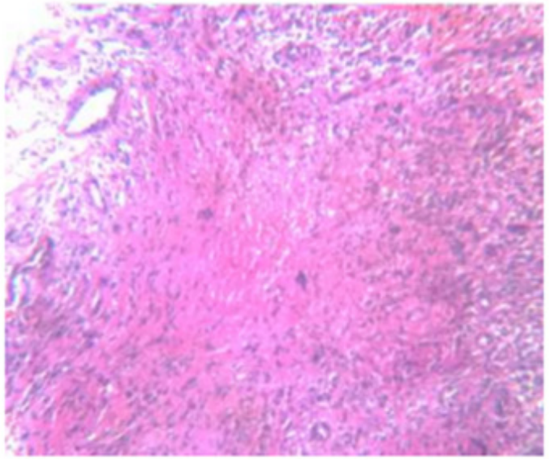

Fig-2: Low power view showing area of necrosis surrounded by granulomatous reaction

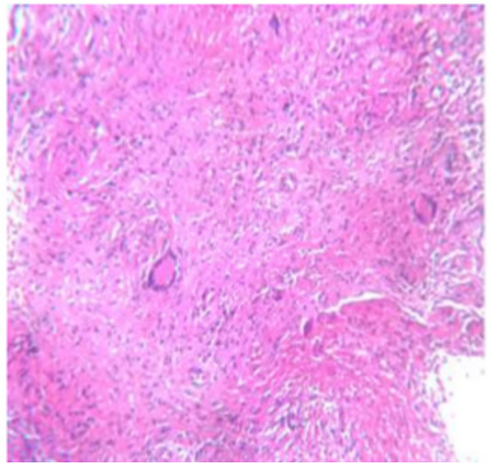

Fig-3: Low power showing a granulomatous reaction composed of langhan type of giant cells, lymphocytes and epitheloid cellls.

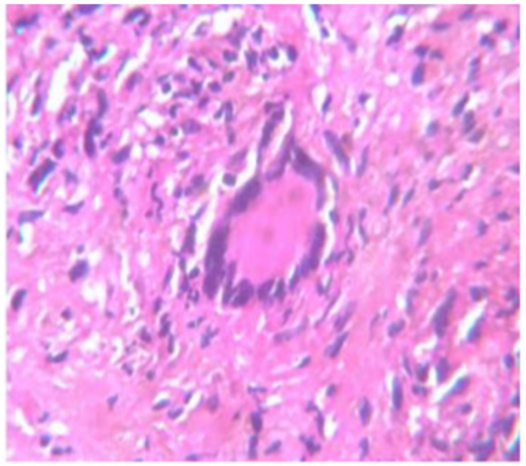

Fig-4: High power view showing a langhan type of giant cells.

Discussion:

Tuberculosis of gastrointestinal tract can involve any portion of bowel extending from oesophagus to anus, though, involvement of bowel distal to ileocecal junction is rarely seen [3]. Tuberculosis around the anus is a rare extrapulmonary form of the disease [4]. While the rate of extrapulmonary tuberculosis has increased in few years (around 5%), the anal presentation still is rare (0.7%) [5]. Anorectal tuberculosis may present in six morphological types of. 1. Fistula in ano 2. Ulcer with undermined edges 3. Stricture 4. Multiple small mucosal ulcers 5. Lupoid form with submucosal nodule and mucosal ulceration 6. Verrucous form with multiple warty excrescences [6]. Due to the diverse presentation of anal TB, it should be considered in all lesions not responding to the standard treatment [7].

Conclusion:

Rectal tuberculosis can mimic a malignant lesion clinically, radiologically and endoscopically. Histopathological study provides the definitive diagnosis of rectal tuberculosis. Repeated biopsies may be required in some cases as tuberculous lesions may be submucosal in nature [8].

In our case also a definite diagnosis was made after a repeat biopsy. An early diagnosis is necessary to prevent recurrences as well as surgeries of such an easily curable disease [7]. Precise diagnosis of extra-pulmonary tuberculosis is essential for better management and to avoid complications.

References:

1. Kandola P, Meena LS; Extra-pulmonary tuberculosis: Overview, manifestations, diagnostic and treatment techniques. Adv Mater Rev. 2014;1(1):13-9.
2. Patil S, Shah AG, Bhatt H, Nalawade N, Mangal A; Tuberculosis of rectum simulating malignancy and presenting as rectal prolapse-a case report and review. 2013; 60: 184-185.
3. Rege SA, Umman P, Nunes Q, Joshi A, Rohandia OS; Rectal tuberculosis simulating malignancy — A Case Report and Review. Bombay Hospital Journal, 2002;44:2.
4. Harland R W, Varkey B; Anal tuberculosis: report of two cases and literature review. American J. Gastroenterology. 1992; 87:1488-1491.
5. Clarke DL, Thomson SR, Bissetty T, Madiba TE, Buccimazza I, Anderson F; A single surgical unit's experience with abdominal tuberculosis in the HIV/AIDS era. World J Surg. 2007; 31:1087-96.
6. Fulton JO, Lazarus C. Varicose anorectal tuberculosis. A case reports. SAMJ. South African medical journal. 1987;71(2):108-9.
7. Bokhari I, Shah SS, Inamullah MZ, Ali SU, Khan A; Tubercular fistula-in-ano. J Coll Physicians Surg Pak. 2008;18(7):401-3.
8. Rasheed S, Zinicola R, Watson D, Bajwa A, McDonald PJ; Intra abdominal and gastrointestinal tuberculosis. Colorectal Disease. 2007;9(9):773-83.

EXPERT OPINION

3. Cognitive bias in histopathology reporting

Dr. Marquess Raj & Dr. Chidambharam Choccalingam,
Department of Histopathology, RRL, Chennai.

"The absence of proof does not constitute the proof of absence."

Rudolf Virchow

Prologue:

The above quote is a conspicuous example of the use of the figure of speech, "Chiasmus'. It can be imagined that Rudolf Virchow intended to touch upon on the vagaries of microscopy& the challenges histopathology reporting can present. A quote similar to the following lines was ubiquitous in pathology circles recently. 'The Pathologist is expected to decipher the absolute truth from a tiny bit fragment of tissue on which the complete exercise of patient management is nestled.' Every biopsy diagnosis is an interpretation of findings pertaining to representative tissue & interpretation is always susceptible to bias.

The corpus of diagnosis in histopathology is made by training the mind & in turn the eye to look for characteristic features & rendering a final verdict. Taking a consensus opinion from colleagues & poring through literature is always an option but still can we be sure that no stone has been left unturned in the exercise involving 'spelling out a diagnosis.'

Cognitive bias & a host of other factors that can impact reporting:

Cognitive bias: The bias that occurs when humans are processing and interpreting information.

While it is commonplace for images such as the one below to be part of personality tests or harmless exchanges in social media. It should be remembered that microscopists too essentially go through a similar process, while sleuthing for findings in their own mental space.

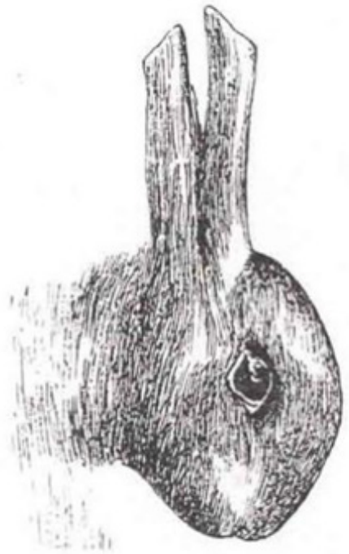

The above image shows a section of appendix with 'subtle pools of mucin' in the lumen. This warrants that the biopsy be studied thoroughly to rule out a low-grade mucinous neoplasm. Just like the second image can be interpreted as a 'duck' or as a 'rabbit', each & everything that meets the eye needs to be interpreted astutely in histopathology.

It is quite possible that the same biopsy can be interpreted differently by separate pathologists even when factors such as pre-analytical error, processing glitches are eliminated & the best of reporting guidelines are adhered to. Reporting guidelines & datasets essentially strive to eliminate inter observer error by the means of making the pathologist sample every significant area, count every single mitosis & look for other every significant finding. However, it is quite possible that a biopsy reported by low grade dysplasia by one pathologist could be reported as high-grade dysplasia by another as interpretation rests on the faculty of perception in a tether held by time. This is just the tip of the iceberg & delving further rather profound questions loom over.

- Does the high expectation of an unfaltering diagnosis pressurize pathologists?
- Does turnaround time compromise thorough study of tissue?
- Is error disclosure embraced by the healthcare fraternity?
- Can QA checks such as EQAS ensure properly proofed reporting?

Small biopsies, for example can challenge even the seasoned pathologist. Superficial study of tissue can even cause veterans to stumble from their high pedestals. Deeper sections often reveal sinister malignancy that are obscure in initial sections. Some tissues such as liver biopsies can be indefinitely studied with a multitude of special stains. With newer IHC markers cropping up round the corner & the molecular mechanisms behind cancer taking centre stage, every other malignancy can be studied in depth to painstaking detail. Given the above facts is it possible to report tissue comprehensively within stipulated timelines every time?

There is a lot of pride at stake for the pathologists if an early malignancy is 'picked up' asit adds credibility to the morphologic acumen of the 'eye of the beholder.'However, when we report a malignancy in a small biopsy and the resected specimen after a major surgery is lying limp on the grossing table, the pathologists heart tends to beat faster. The heart beat raises further when the pathologist grosses and sees no obvious gross pathology.

Nevertheless, giving sections and waiting to see what we are going to stare under the microscope is a nightmare. Do wepray that we see a malignancy to take stock of our initial diagnosis in the small biopsy and bask in the glory of giving an accurate diagnosis, or do we rejoice that there is no tumor and patient is disease free? Situations such as the one above aretesting times when the dilemma as to whether one has to choose between being a good pathologist & a good human being.

Faltering at giving the perfect diagnosis can break the reputation bubble of individuals as well as organizations. However, it needs to be emphasized that even histopathology has gray areas & errors of reason or even nuance can creep in. Error disclosure should be encouraged & the same should be discussed in multidisciplinary meetings so that it paves a way to improving patient safety.

Though the authors embrace QA processes & their application in histopathology practice. Skepticism remains as to how a handful of lesions or a flurry of images can provide adequate sampling of a branch which probably has the most voluminous literature in the whole of medicine.

Final Thoughts:

Histopathology reports are hard evidence. Much alike a CCTV camera captures a speeding car. Evidence of disease is frozen on a glass slide & the same is documented as a report. Though advancements in histopathology augur well for patients it should be emphasized that pathologists have to stay abreast of the times, constantly sharpeningtheir diagnostic acumen & preparing themselves to face challenging moments.

4. Quiz – Every lining has a name

Dr. Marquess Raj & Dr. Shalini Singh - Co-editors AD express

Owing to complex anatomy of the anogenital area in females, vulvar cysts can have a variety of epithelia depending on from where they arise. Vulvar cysts being a frequent specimen in surgical pathology, basic knowledge of the types of epithelia encountered in the different types of cysts is vital. Almost all of the accessory sex organs have specific counterparts in both genders. For example, the paraurethral glands of Skene are homologous to the prostatic glands. Similarly, pathology reminiscent of male accessory organs can occur inn females. For example, cyst of the canal of nuck is analogous to hydrocele of the spermatic cord. Though epidermoid cysts are the most common cyst encountered in the vulva, cysts representative of the accessory sex organs can also arise.

Match the type of epithelium with the vulvar cyst (Same option can be used multiple times)

1. Bartholin duct cyst A. Squamous
2. Pilonidal cystB. Transitional
3. Hymenal cystC. Mesothelium
4. Canal of nuck cystD. Non mucus cuboidal
5. Gartner duct cystE. Hair follicle wall

Answers to the pervious quiz in the September 23 issue:

The following tests are matched to the correct methodology

1. HbA1C	A. HPLC
2. Serum creatinine	B. Spectrophotometry
3. Hemoglobin estimation	C. Colorimetric
4. Blood culture	D. Automation
5. C3	E. Nephelometry

5. Quiz: What's on the stage?

Dr. Veena Singh, Consultant Pathologist, RHCC, Ambattur, Chennai

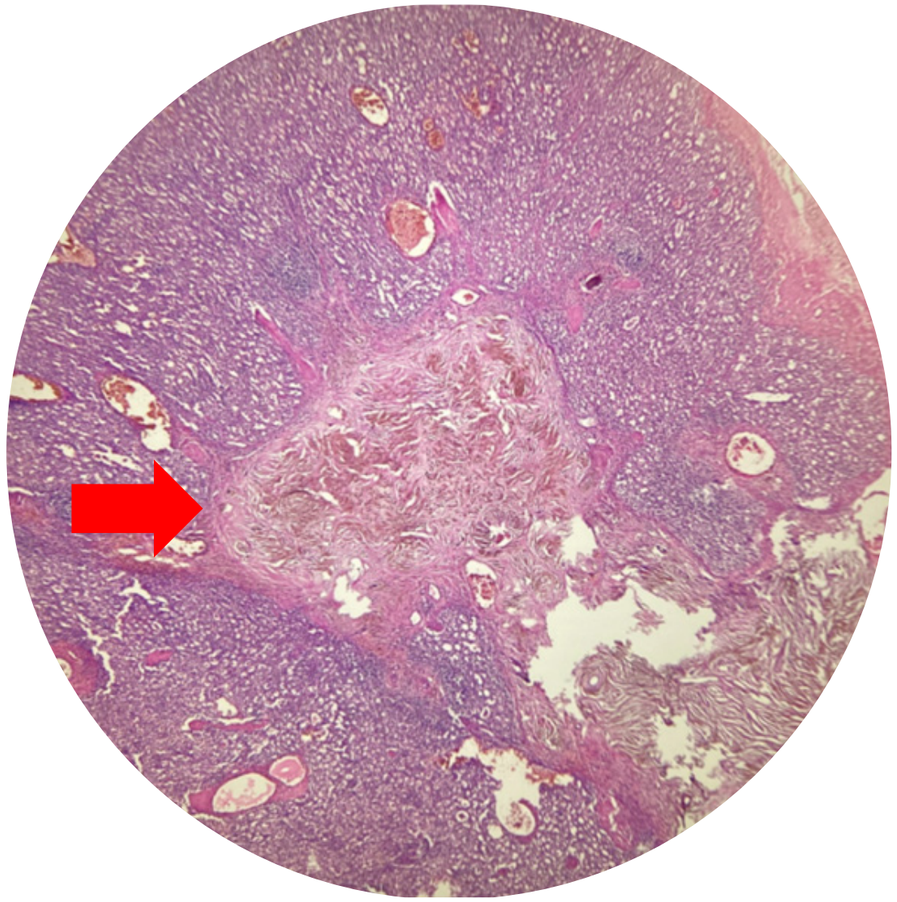

A. The red arrow points to what pathognomic histopathology finding in the photomicrograph from a spleen section is given. A brief of the same shall be given in the next issue.

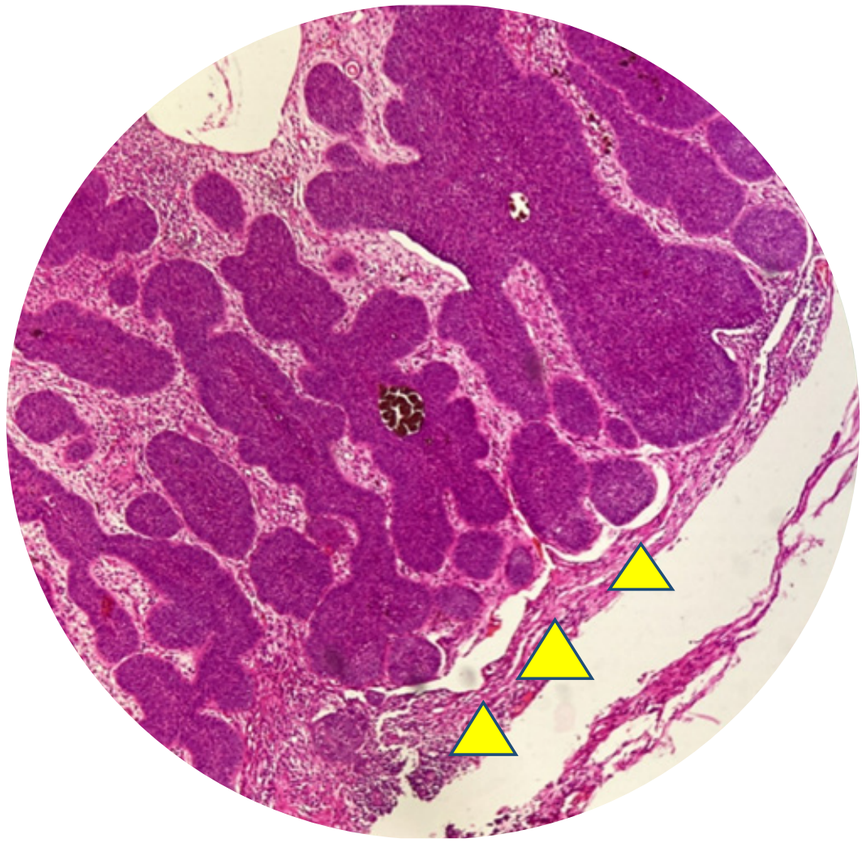

B. Answer to the photomicrograph from the previous issue: Basal cell carcinoma

Characteristic histopathological features show nodules of basaloid cells & the characteristic retraction artefact (Yellow arrows).

CME and Conference Conducted

CME at Agra

Conference with Society of Fetal medicine in Kolkata

CME in Mysore

CME at Kasaragod

RTM in Assam

Apollo DIAGNOSTICS®

Expertise. Empowering you.